



Salivary Gland Neoplasms
Arizona Society of Pathologists
October 1, 2016

Bruce M. Wenig, MD
Mount Sinai Health System
New York, NY

Salivary Gland Neoplasms Outline

- Pleomorphic Adenoma and Carcinoma ex Pleomorphic Adenoma
- Mucoepidermoid Carcinoma
- Acinic Cell Adenocarcinoma
- Mammary Analogue Secretory Carcinoma
- Adenoid Cystic Carcinoma
- Polymorphous Low-Grade Adenocarcinoma

Features of Benign & Malignant Salivary Gland Neoplasms

- Encapsulation and circumscription:
 - All major gland neoplasms are encapsulated:
 - Benign → Noninvasive
 - Malignant → Invasive; exceptions include:
 - Mucoepidermoid carcinoma
 - Acinic cell adenocarcinoma
 - Adenoid cystic carcinoma
 - Mammary analogue secretory carcinoma
 - Epithelial-myoepithelial carcinoma
 - Noninvasive carcinoma ex pleomorphic adenoma

Features of Benign & Malignant Salivary Gland Neoplasms

- Encapsulation and circumscription:
 - All minor gland neoplasms are unencapsulated
 - Presence or absence of invasion: neurotropism, LVI, salivary gland parenchyma, soft tissue, bone
 - Specific tumor-type defined by cytomorphology (MEC, ACC, others)

Salivary Gland Neoplasms Shared Features

- Growth patterns:
 - ALL salivary gland neoplasms are polymorphic
- Cytomorphology:
 - Isomorphic cell type(s) lacking significant nuclear pleomorphism, increased mitotic activity
- Dual cell composition:
 - Many neoplasms composed of epithelial & myoepithelial cells:
 - Light microscopy
 - IHC: cytokeratins, p63, p40, calponin, S100 protein

Intraoral Minor Salivary Gland Neoplasms Biopsies

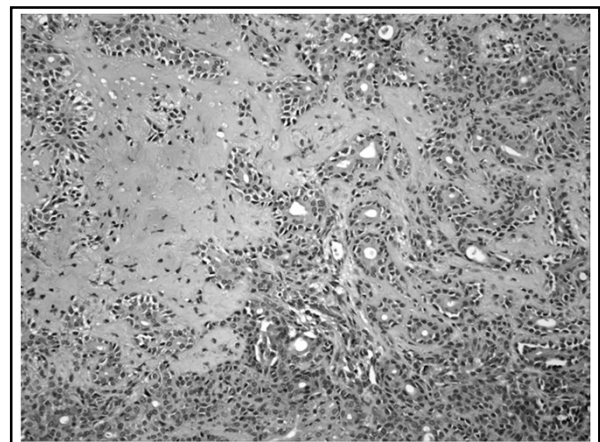
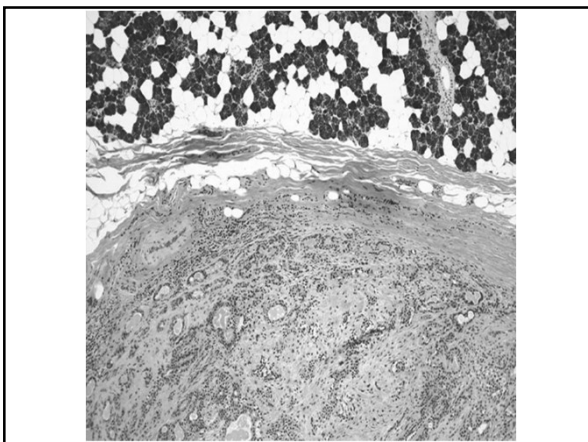
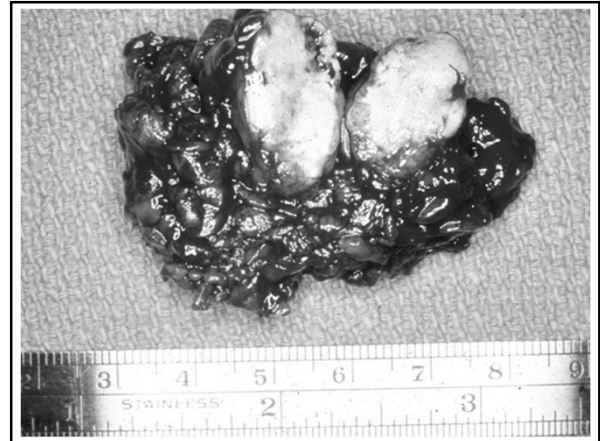
- In limited biopsies especially those without surrounding tissue to evaluated for invasion, differentiation often cannot be achieved as these neoplasms share overlapping:
 - Growth patterns
 - Cytomorphology
 - Cell composition
 - Immunohistochemical reactivity

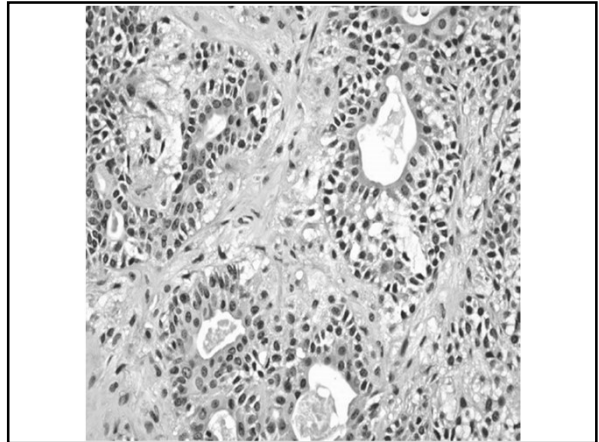
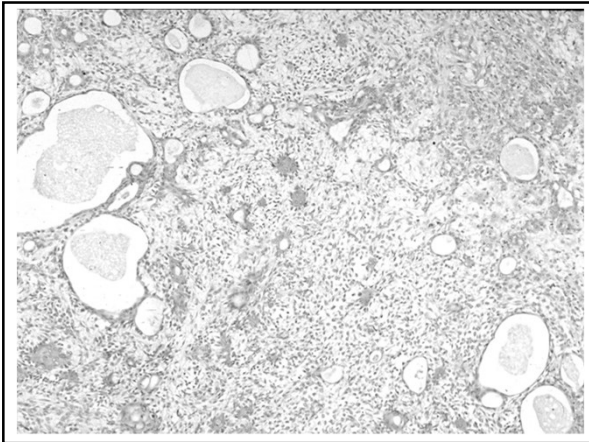
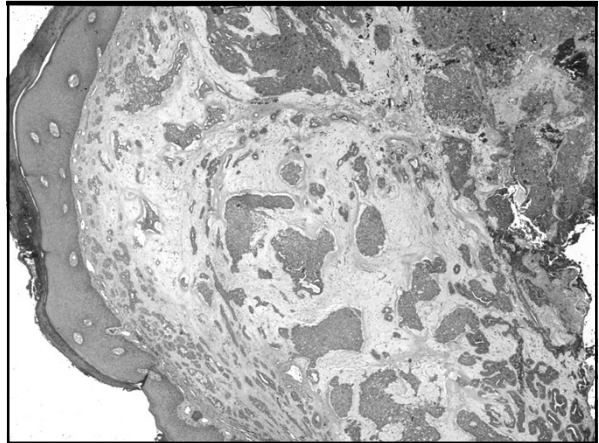
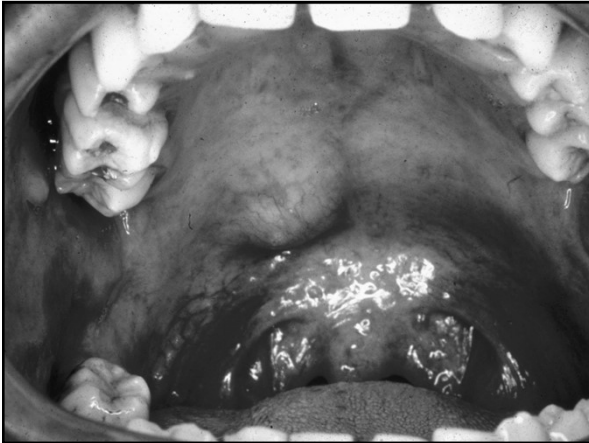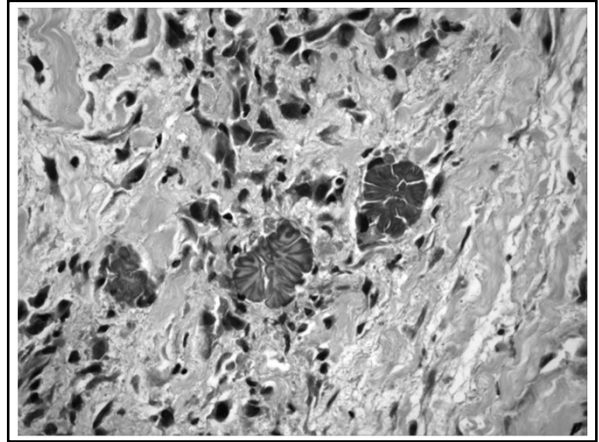
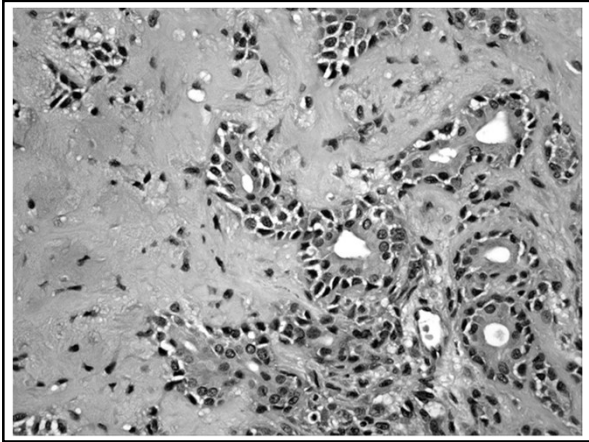
Pleomorphic Adenoma (PA) Definition

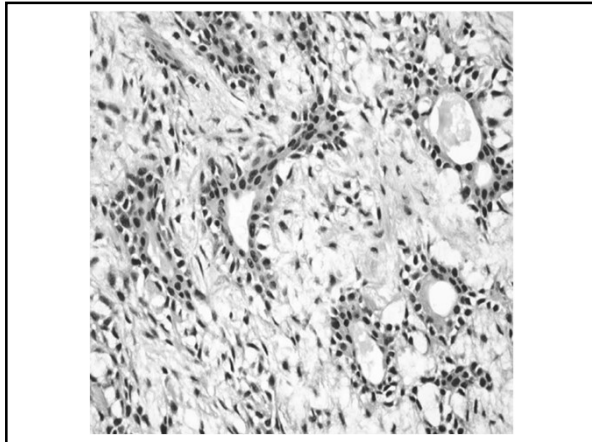
- Benign epithelial-derived tumor with epi- and myoepithelial differentiation, and variable amount mesenchyme (stroma):
 - tubular/ductular structures enveloped by myoepithelial cells with associated copious chondromyxoid stroma
- Aka – Benign Mixed Tumor

Pleomorphic Adenoma (PA) Clinical Features

- Most common salivary gland neoplasm
- F > M; wide age range including children
- Sites: major glands and minor glands
- Symptoms:
 - slow growing painless mass
 - airway obstruction, dysphagia, epistaxis


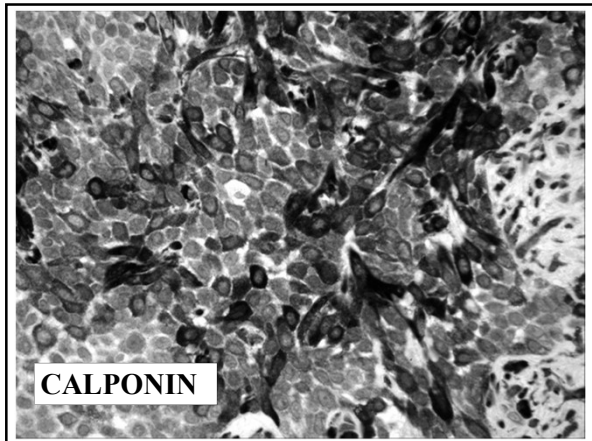
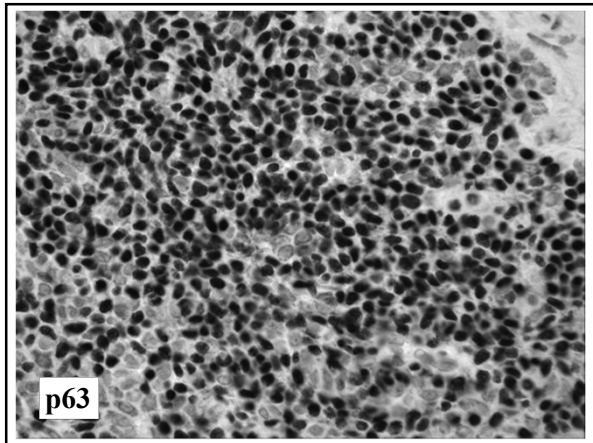
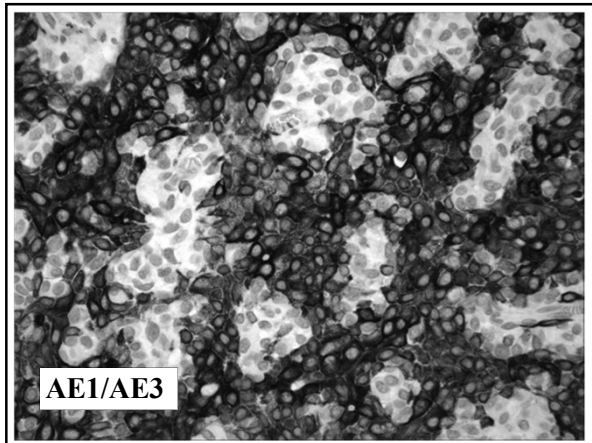


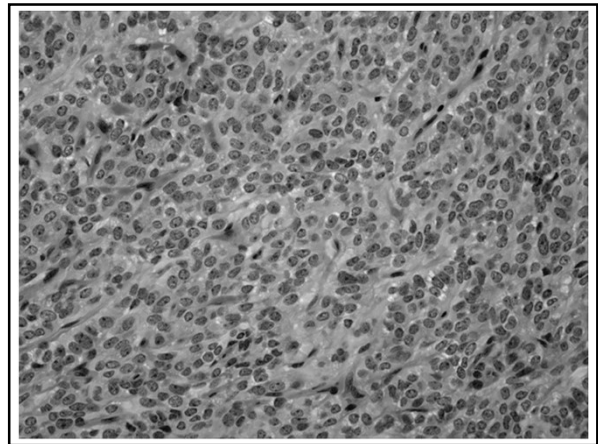

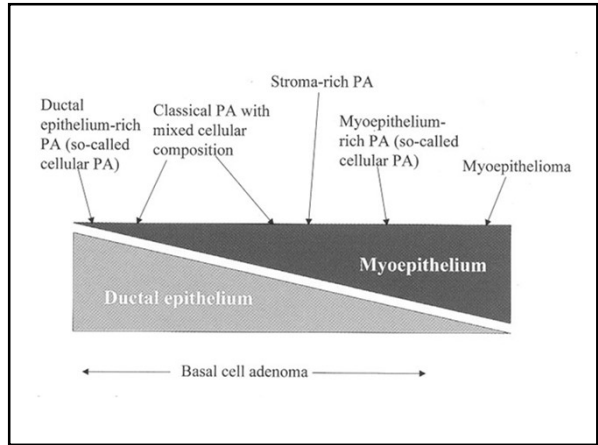
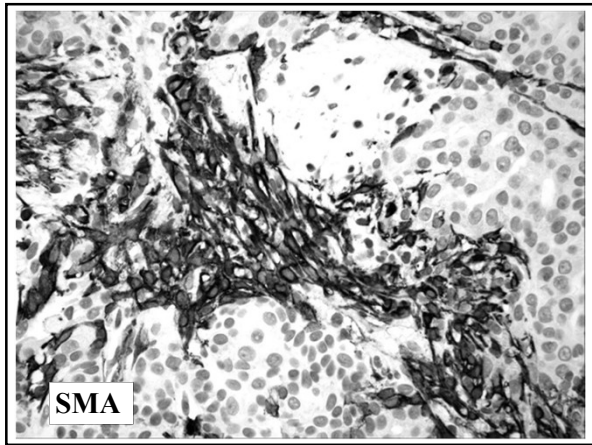
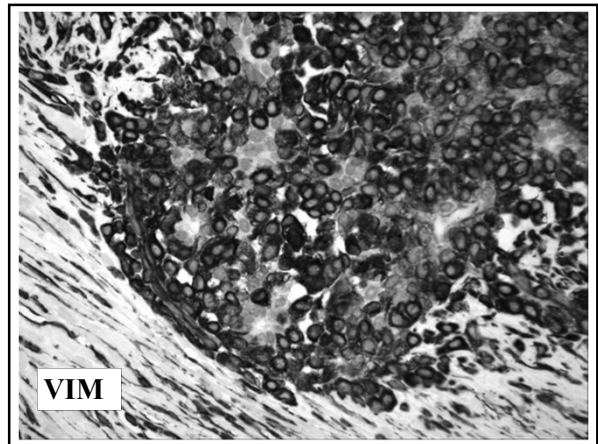
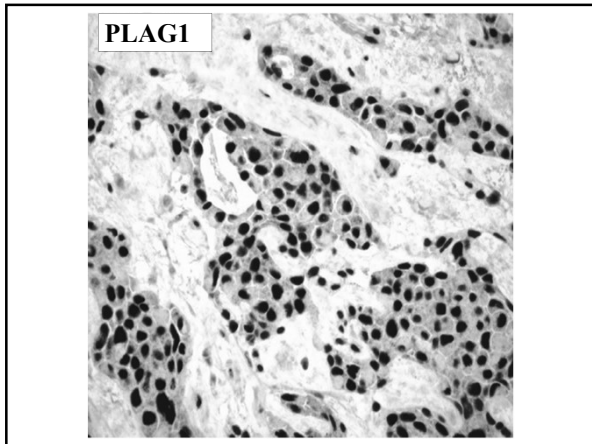


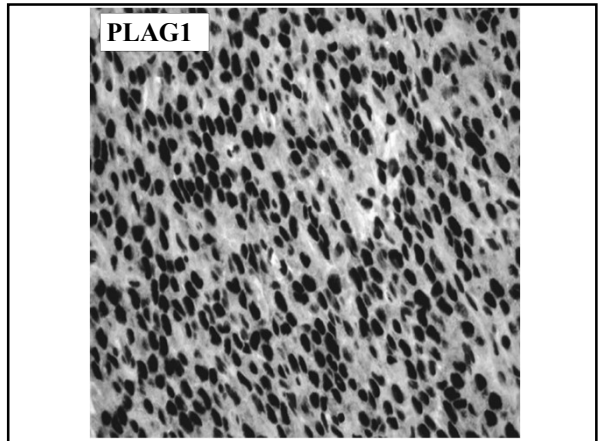
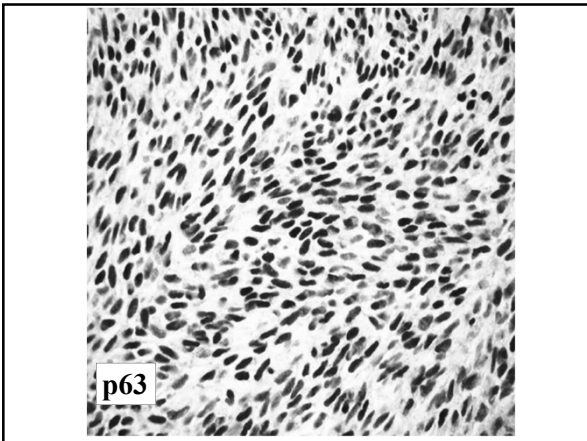
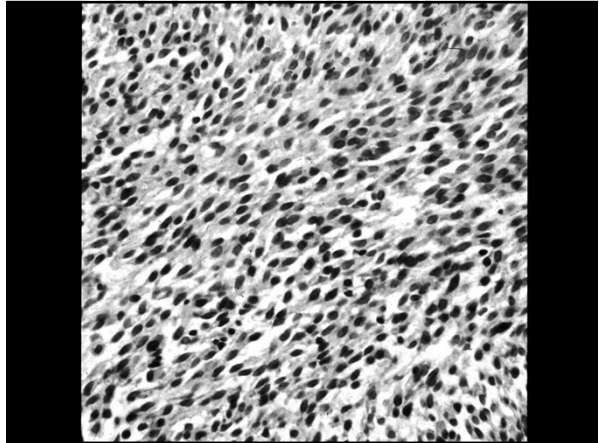
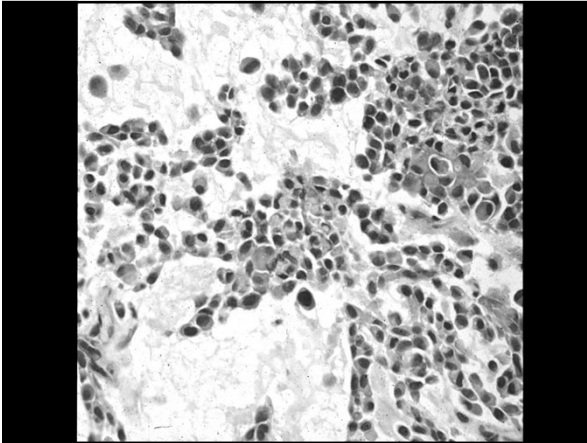
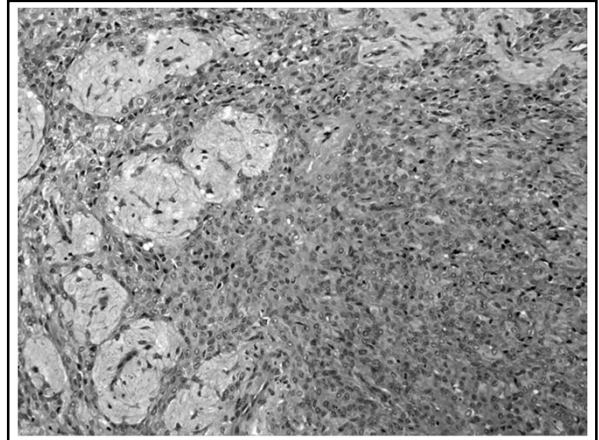
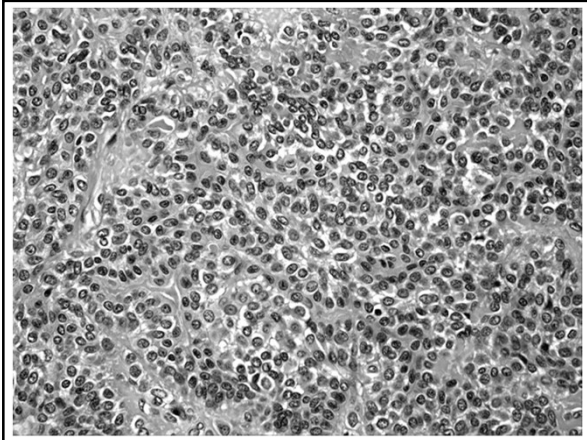


**Pleomorphic Adenoma (PA)
Immunohistochemistry**

- **Epithelial cells:**
 - cytokeratins; EMA; CEA
 - pleomorphic adenoma gene 1 (PLAG1)
- **Myoepithelial cells:**
 - cytokeratins
 - p63, p40, S100 protein, PLAG1
 - vimentin, calponin, GFAP, SMA, MSA, SMMS



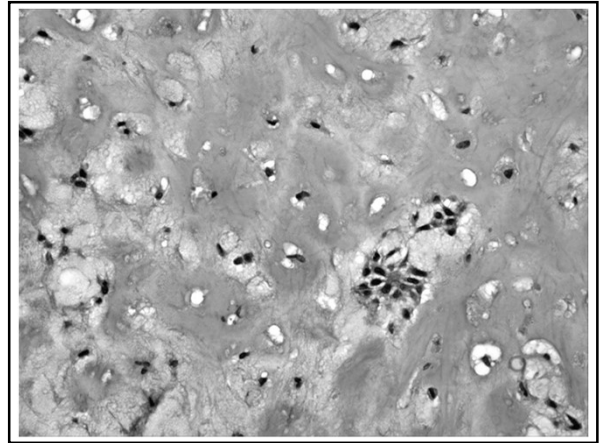
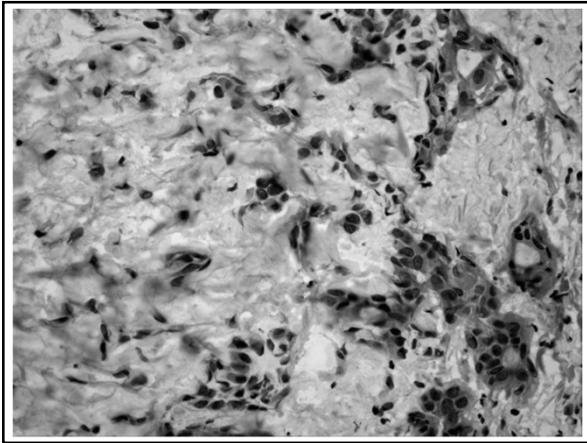
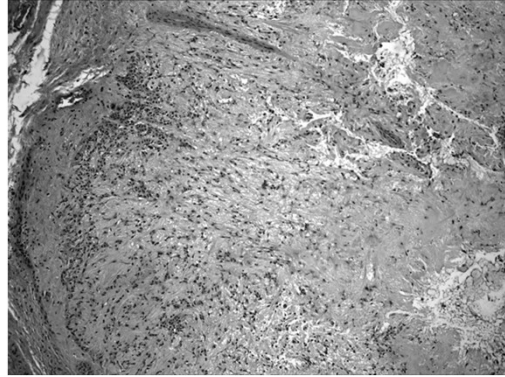




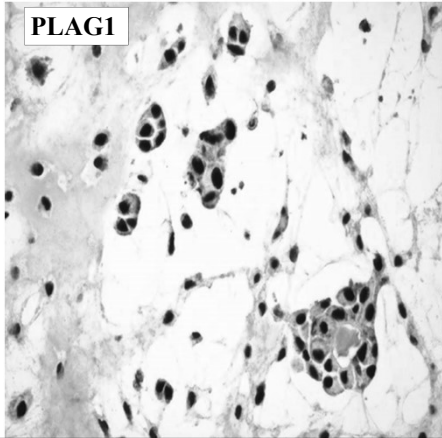
Pairing p63 and p40

- IHC pairing p63 and p40 reported to assist in differentiating pleomorphic adenoma (PA) from polymorphous low-grade adenocarcinoma (PLGA) and adenoid cystic carcinoma (AdCC)
 - PA: p63 +; p40+
 - Cellular PA: p63+; p40+ or p63- ; p40-
 - PLGA: p63+; p40-
 - AdCC: p63 +; p40+

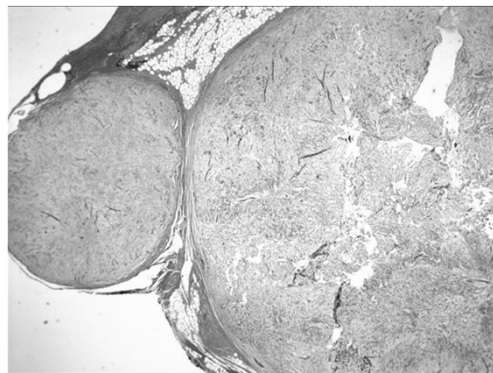
Chondromyxoid-Predominant PA

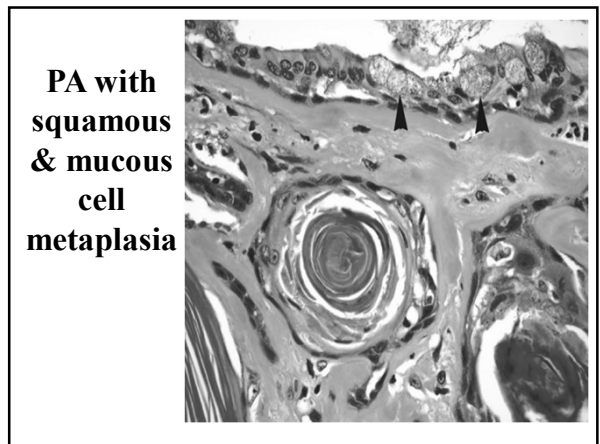
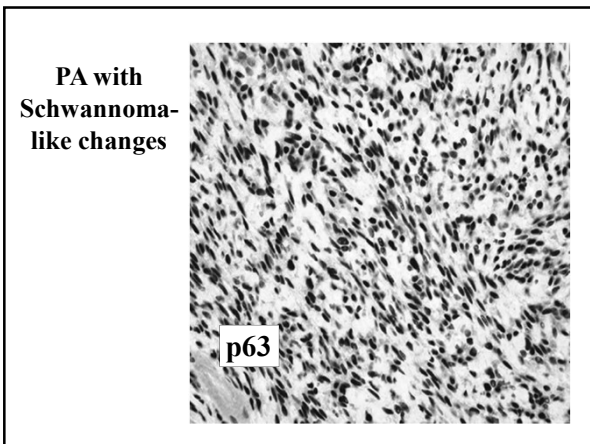
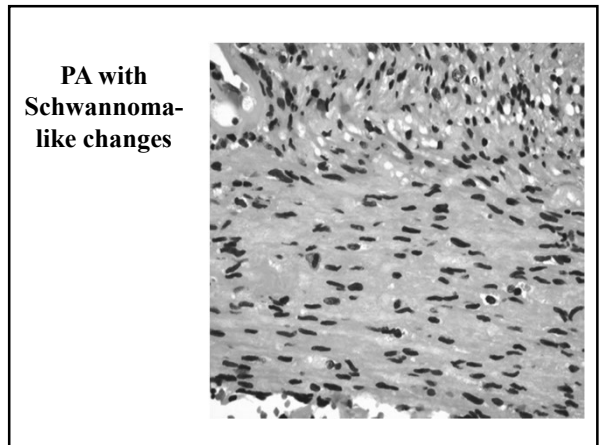
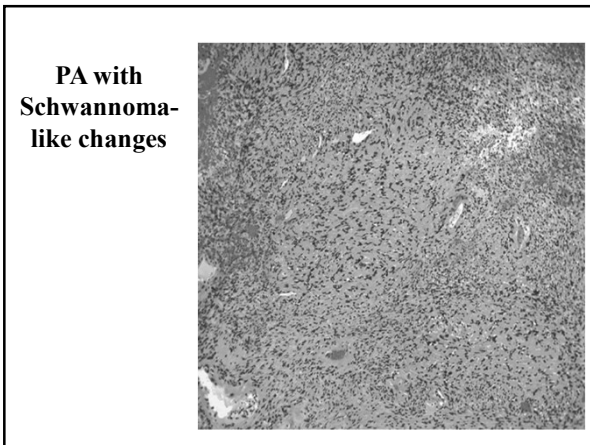
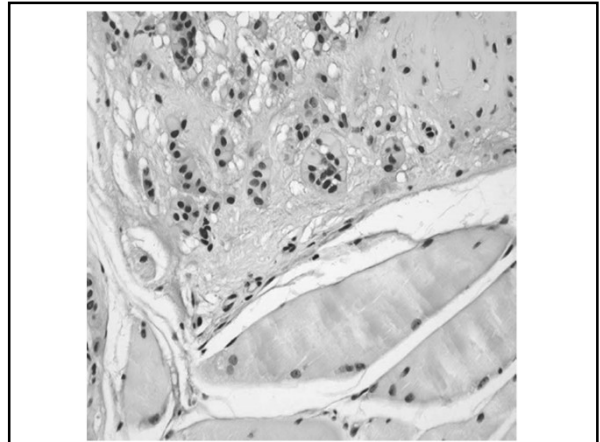
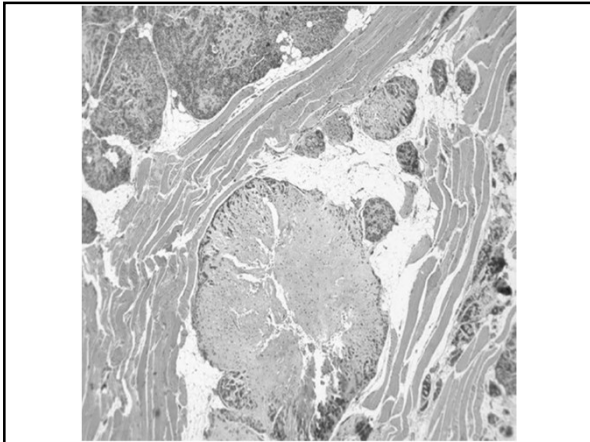


PLAG1

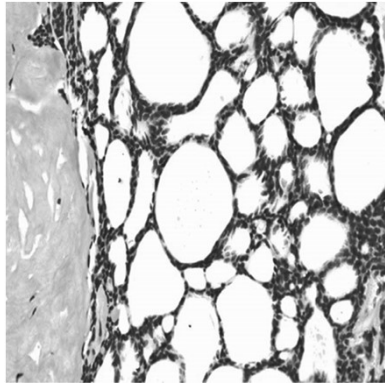


Multinodular PA

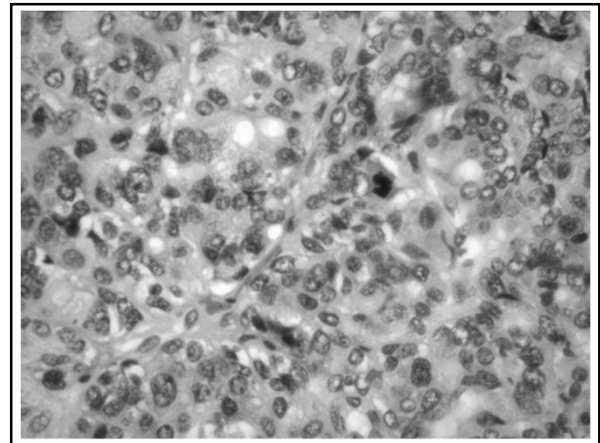
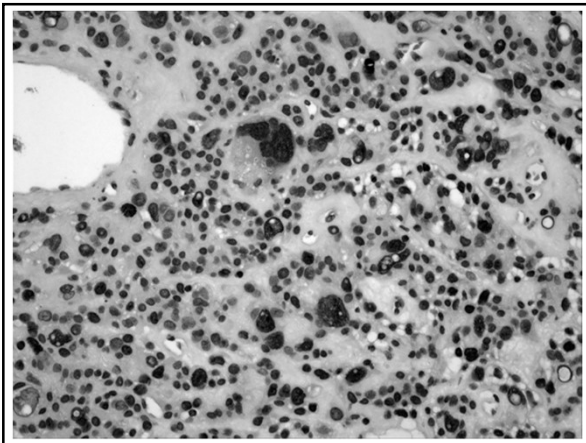
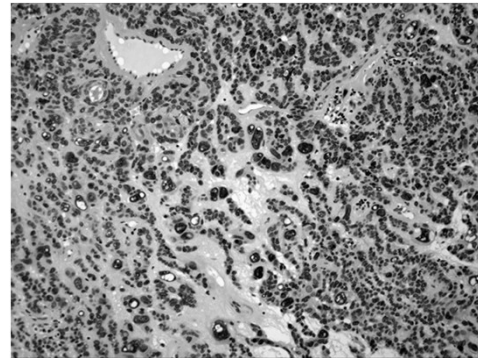




PA with cribriform growth



PA with “monster” nuclei

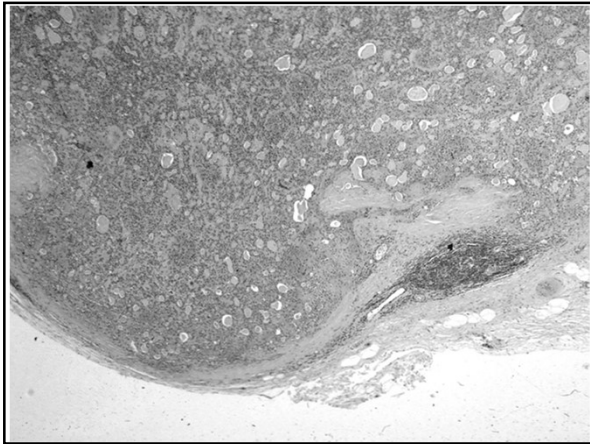


**Pleomorphic Adenoma (PA)
Treatment and Prognosis**

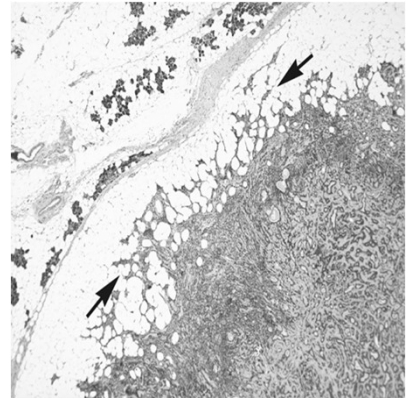
- Surgical resection
- Recurrence-free rates:
 - 5 year = 97%
 - 10 year = 94%
- Recurrences:
 - histology similar to primary
 - may be chondromyxoid rich/predominant
 - may be multinodular including nodules in soft tissues of the neck

**Pleomorphic Adenoma (PA)
Atypical Features**

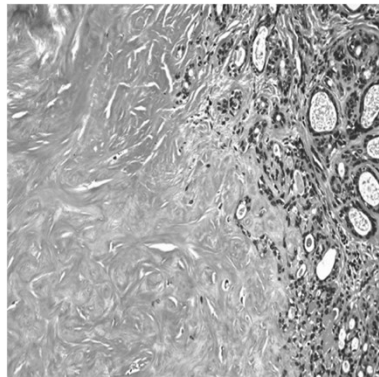
- PAs that include atypical features but fall short for a diagnosis of carcinoma ex pleomorphic adenoma:
 - diffuse nuclear atypia
 - increased mitotic figures
 - irregular growth along periphery
 - foci of acellular hyalinization



**PA
extending
into +/-
with
associated
fat**

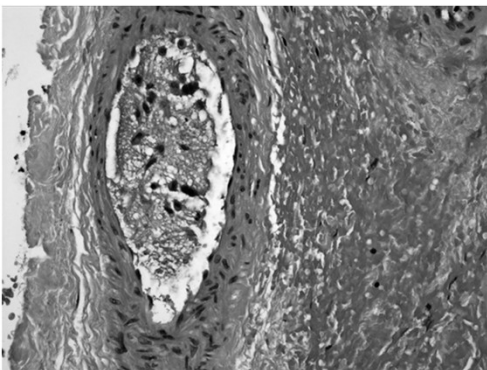


**PA with
acellular
hyalinization
↓
submit entire
tumor**



Atypical Pleomorphic Adenoma Treatment and Prognosis

- Similar to Pleomorphic Adenoma



PA Features that may be associated with malignancy

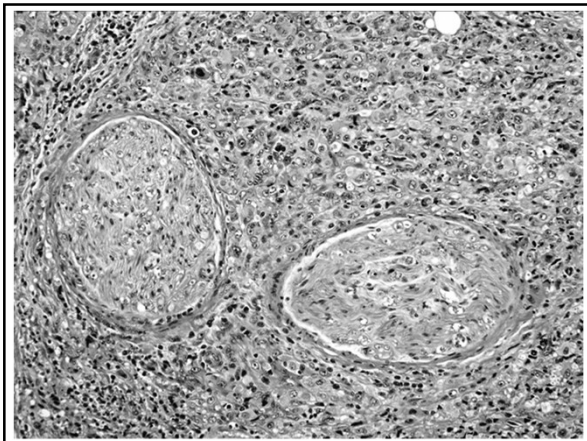
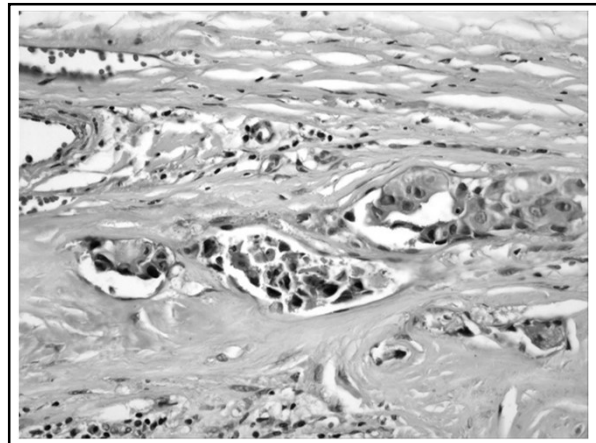
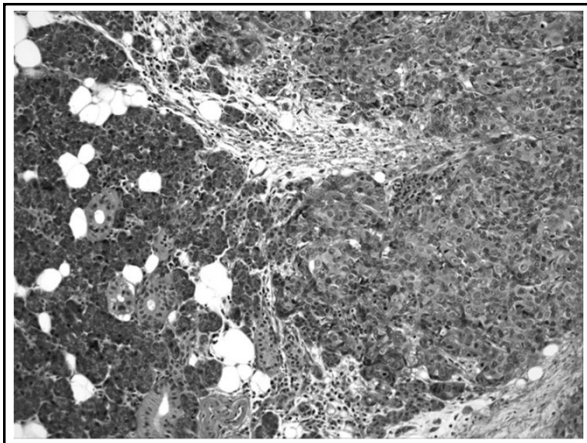
- **Clinical:**
 - Older patient
 - Long-standing tumor
 - Larger tumor
 - Submandibular gland

PA
Features that may be associated with malignancy

- **Pathology:**
 - **Hypercellularity with diffuse anaplasia**
 - **Increased mitotic activity, atypical mitoses**
 - **Prominent zones of hyalinization; necrosis**

Malignancy in PA
Histologic Criteria

- **Definitive:**
 - **Invasive growth (LVI, PNI, invasion of adjacent gland and/or soft tissues)**
 - **Metastatic disease**
- **Carcinoma ex pleomorphic adenoma (CEPA)**

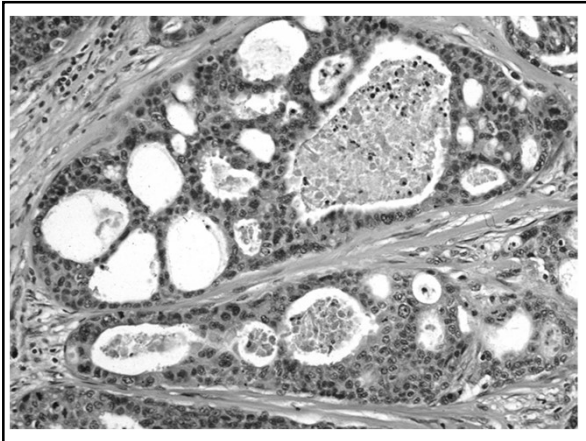
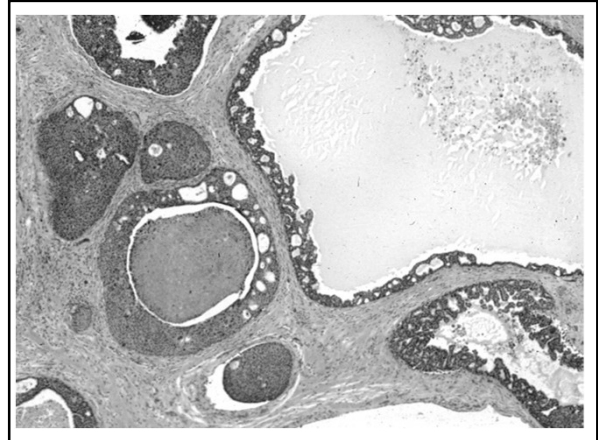

CEPA
Histology

- **Carcinoma arising in/from a PA:**
 - **High-grade**
 - **Low-grade**
 - **Invasive**
 - **Non-invasive (intracapsular)**

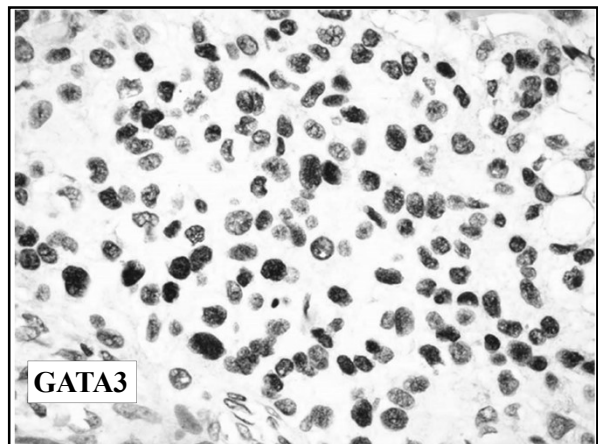
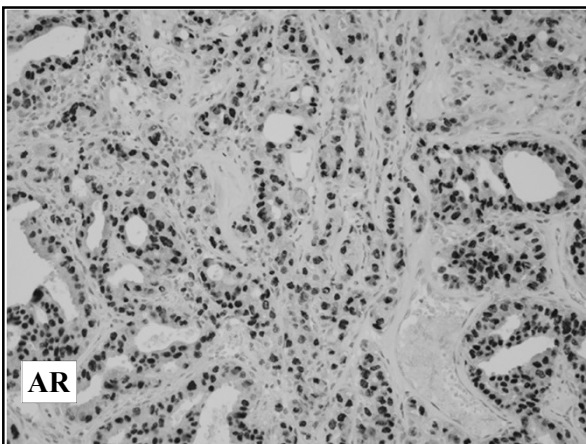
**CEPA
Histology**

- Carcinoma arising in/from a PA:
 - residual PA readily identifiable to absent
- Malignant component:
 - High-grade:
 - Salivary duct carcinoma; undifferentiated, poorly-differentiated adenocarcinoma, squamous cell carcinoma



**Salivary Duct Carcinoma
Immunohistochemistry**

- Cytokeratins, EMA, CEA positive
- Androgen receptor positive
- GATA3 positive
- BRST-2 positive
- Her-2/neu positive (membranous)
- ER and PR positive (minority)
- S100 protein, p63, calponin, SMA, vimentin negative
- Rare neuroendocrine differentiation
- PSA and PAP may be positive
- High proliferative index (25-80%) by Ki-1



CEPA Histology

- **Malignant component:**
 - **Low-grade:**
 - MEC, PLGA, acinic cell adenocarcinoma, adenoid cystic carcinoma, myoepithelial carcinoma, others

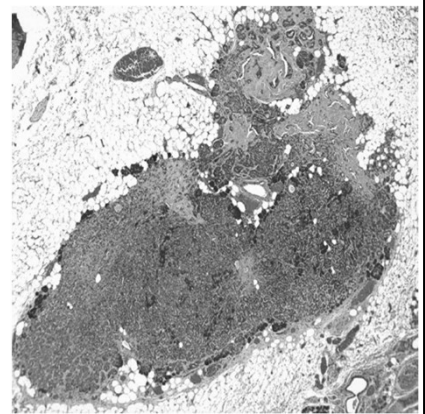
Intracapsular or Noninvasive CEPA

- Salivary gland pleomorphic adenoma with foci of cytomorphic malignant cells but without evidence of invasion
- Early stage in the development malignant transformation of pleomorphic adenoma
- **Must submit entire tumor to exclude invasion**
- **In absence of invasion prognosis considered very good**

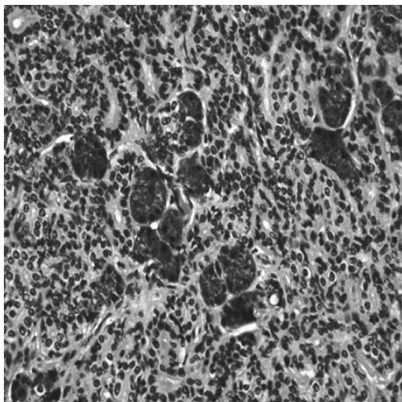
CEPA Prognostic Factors

- **Origin in major glands**
- **Recurrent or metastatic disease**
- **Penetration of capsule:**
 - invasion beyond 1.5 mm from capsule associated with poor outcome
 - invasion less than 1.5 mm associated with no recurrence or metastases
- **Surgical Margins**
- **Histologic grade**

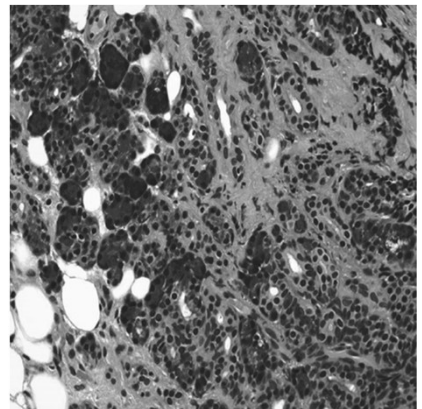
**Intercalated
Duct
Hyperplasia**



**Intercalated
Duct
Hyperplasia**



**Intercalated
Duct
Hyperplasia**

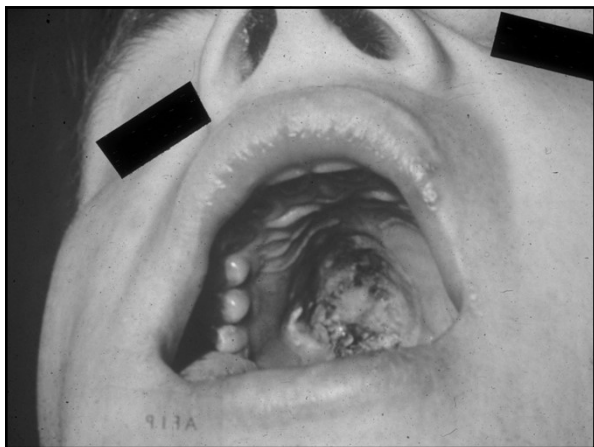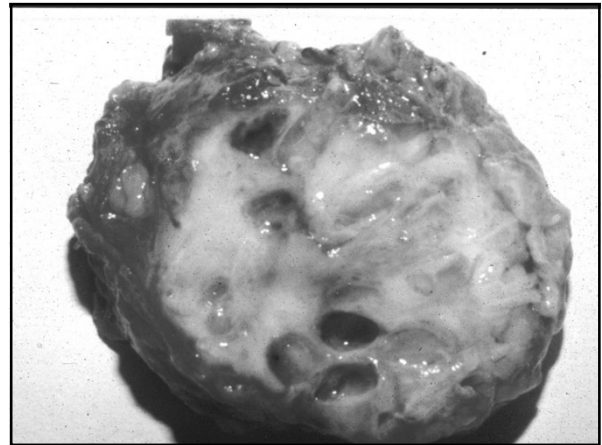
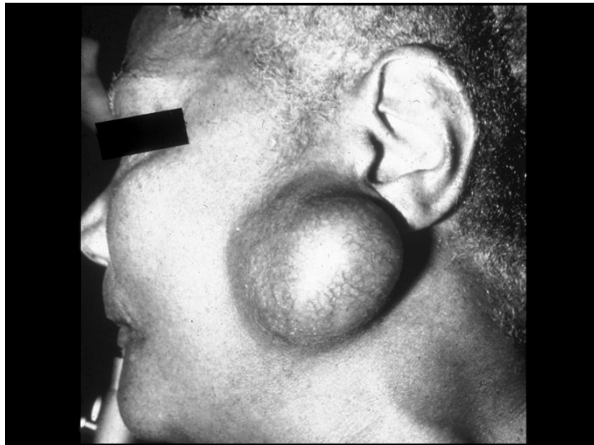


**Mucoepidermoid Carcinoma (MEC)
Definition**

- Malignant epithelial salivary gland tumor composed of epidermoid, mucous and intermediate cells

**Mucoepidermoid Carcinoma
Clinical Features**

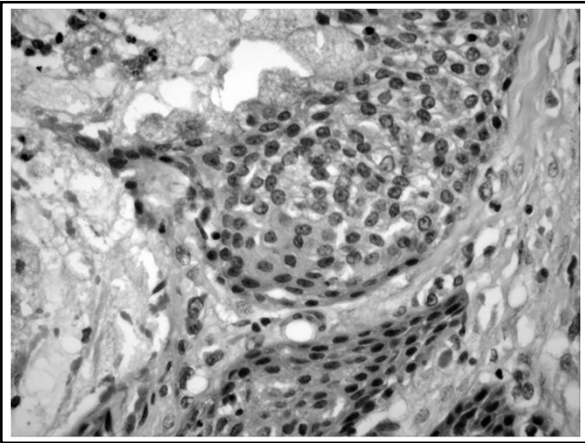
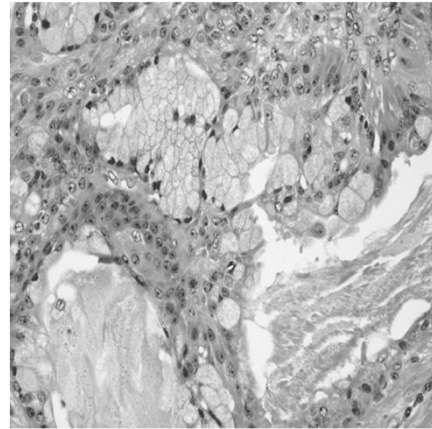
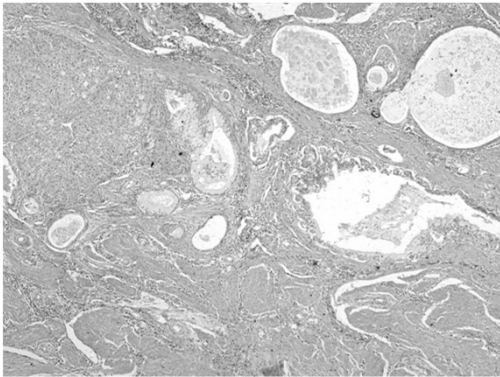
- Most common malignant salivary gland neoplasm
- F > M; 3rd - 5th decades
 - Most common pediatric malignant SG tumor
- Major gland - Parotid; Minor gland - palate
- Up to 2/3 of patients may be asymptomatic



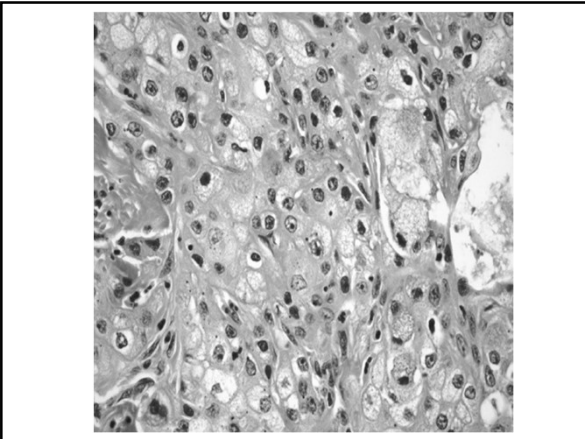
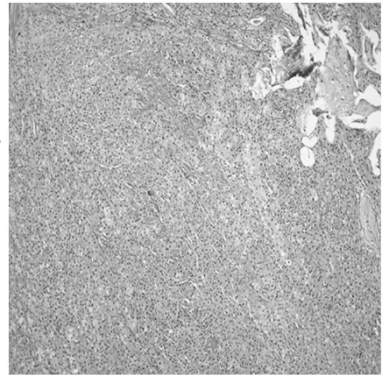
**Mucoepidermoid Carcinoma (MEC)
Histologic Grading**

- Low-grade
- Intermediate grade
- High-grade

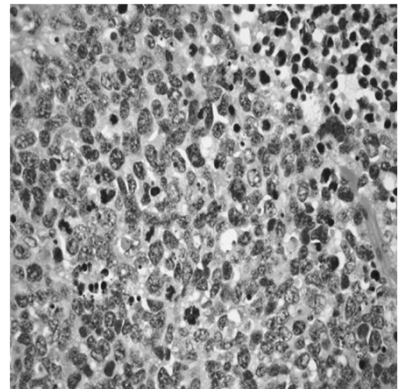
MEC, low-grade

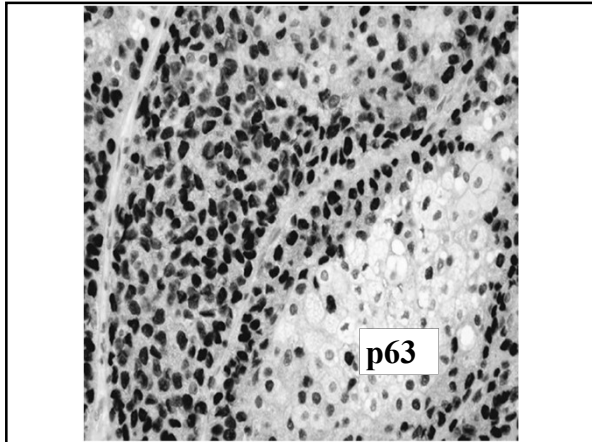


**MEC,
intermediate-
grade**



**MEC, high-
grade**





**Mucoepidermoid Carcinoma
Microscopic Grading**

- Proportion of cystic component relative to solid component
- Proportion of cell type
- Cellular maturation
- Mitoses
- Pattern of invasion
- Necrosis

**Mucoepidermoid Carcinoma
*Microscopic Grading**

- Intracystic component <20% 2
- Neural invasion 2
- Necrosis present 3
- 4 or more mitoses 3
- Anaplasia 4

* Auclair, Goode, Ellis. Cancer 1992;69:2021-30
* Goode, Auclair, Ellis. Cancer 1998;82:1217-24

**Mucoepidermoid Carcinoma
*Microscopic Grading**

- Low-grade 0-4
- Intermediate grade 5-6
- High grade 7 or more

* Auclair, Goode, Ellis. Cancer 1992;69:2021-30
* Goode, Auclair, Ellis. Cancer 1998;82:1217-24

**Mucoepidermoid Carcinoma
*Microscopic Grading**

- Intracystic component less than 25% 2
- Tumor front invades in small nests and islands 2
- Pronounced nuclear atypia 2
- LVI 3
- Bony invasion 3
- 4 or more mitoses 3
- Perineural invasion 3
- Necrosis 3

* Brandwein et al. AJSP 2001;25:835-45

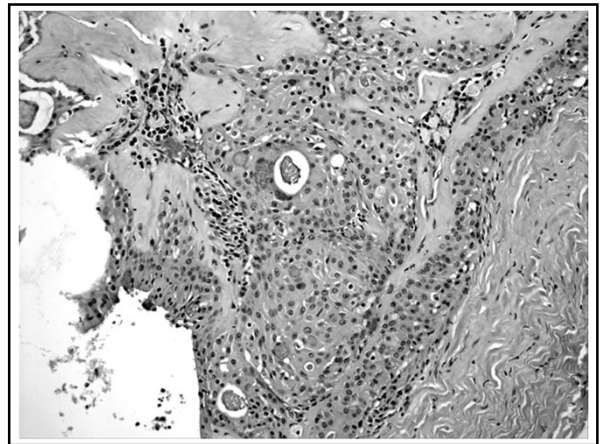
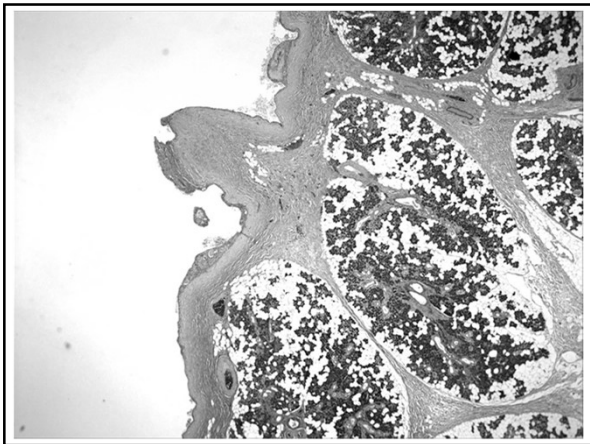
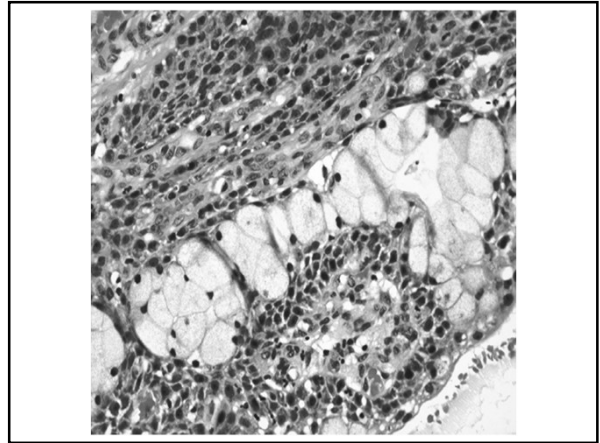
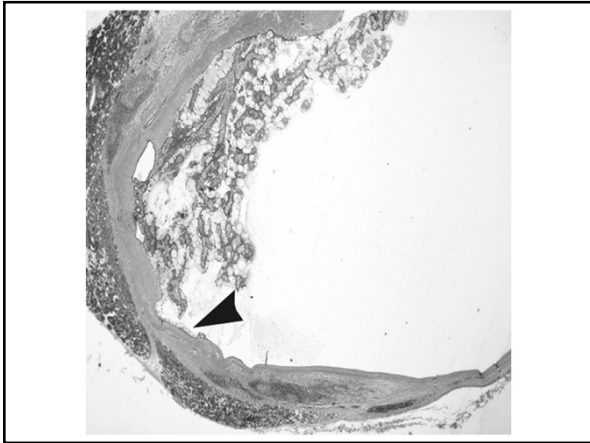
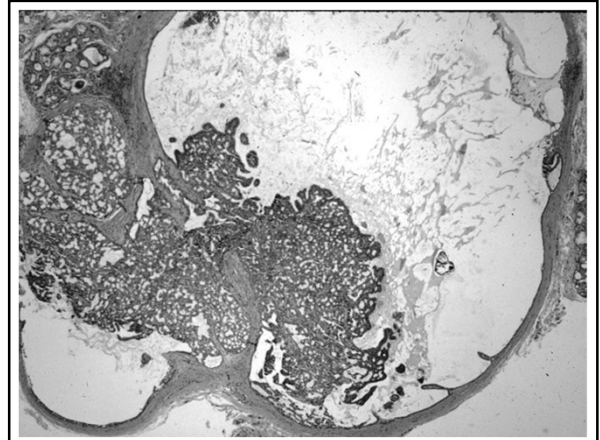
**Mucoepidermoid Carcinoma
*Microscopic Grading**

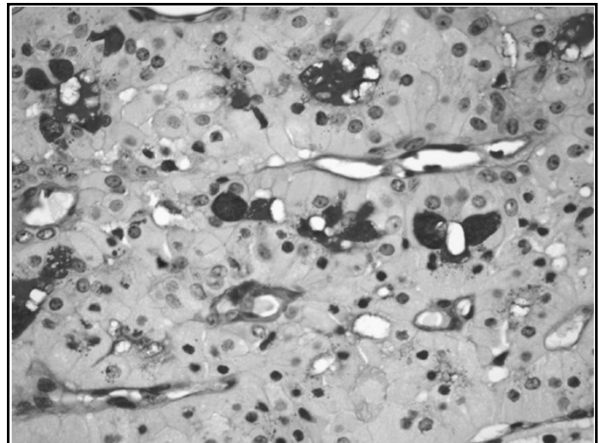
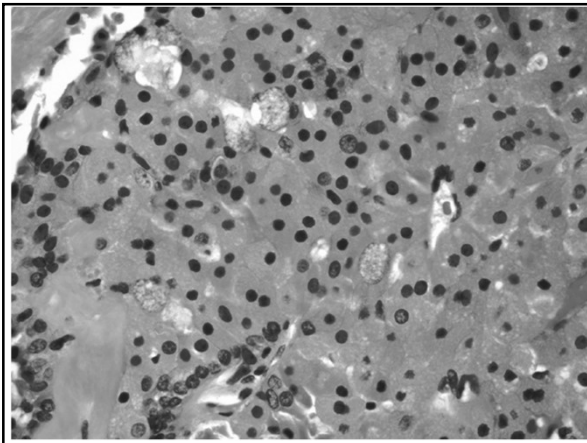
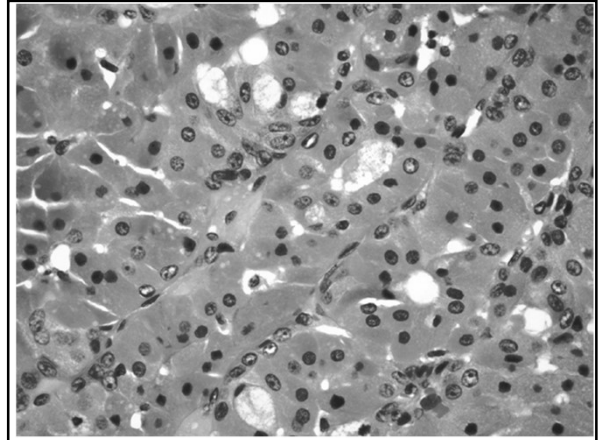
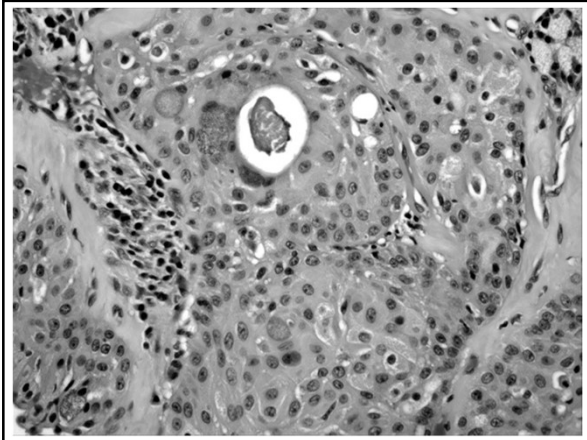
- Low-grade 0
- Intermediate grade 2-3
- High grade 4 or more

* Brandwein et al. AJSP 2001;25:835-45

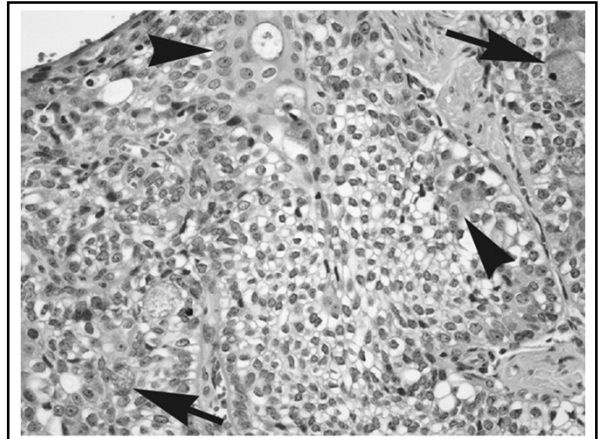
MEC - Histologic Variants

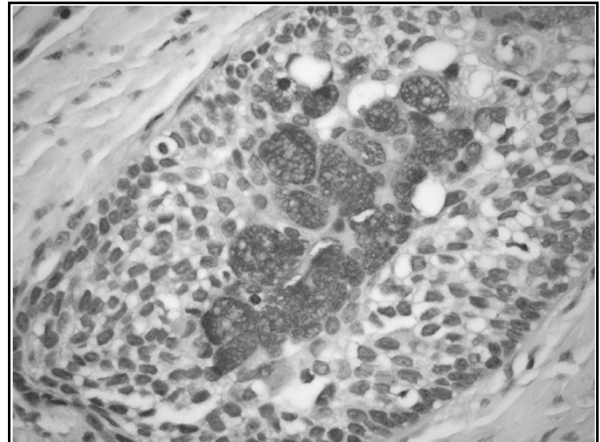
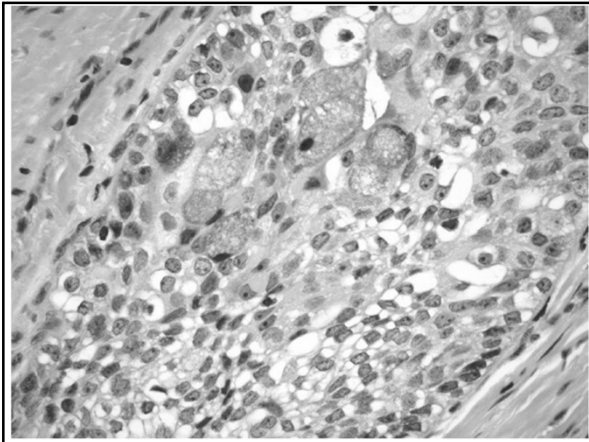
- Cystic
- Oncocytic
- Clear cell
- Sclerosing
 - with and without eosinophilia





- Salivary Gland Tumors with Oncocytic Cells**
- Oncocytoma; oncocytosis
 - Pleomorphic and monomorphic adenomas
 - Acinic cell adenocarcinoma
 - Mammary analogue secretory carcinoma
 - Mucoepidermoid carcinoma
 - Oncocytic carcinoma
 - Salivary duct carcinoma

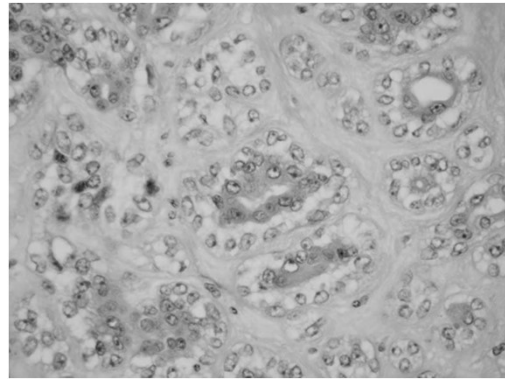




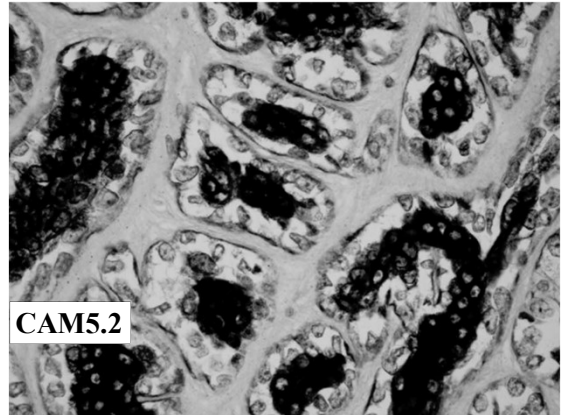
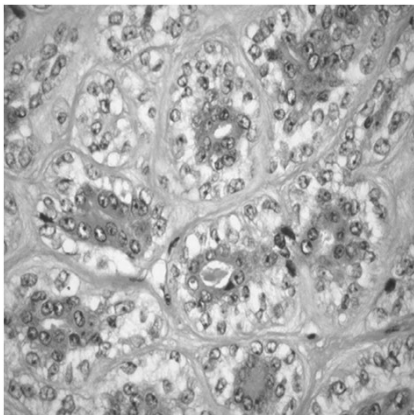
Salivary Gland Tumors with Clear Cells

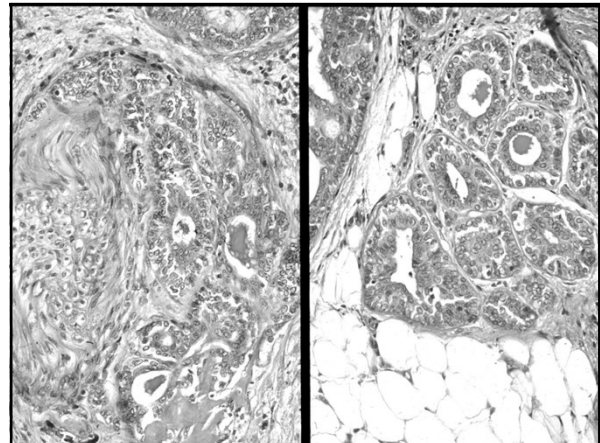
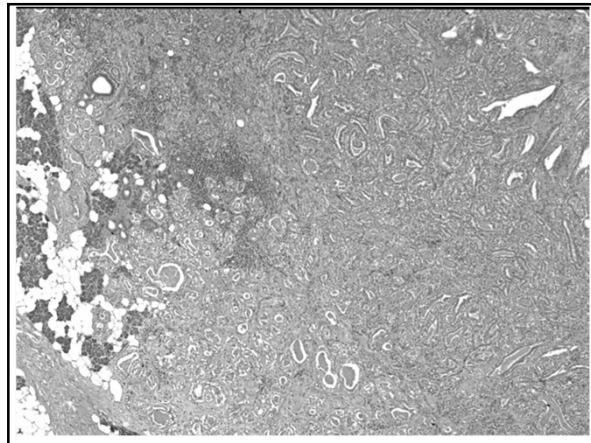
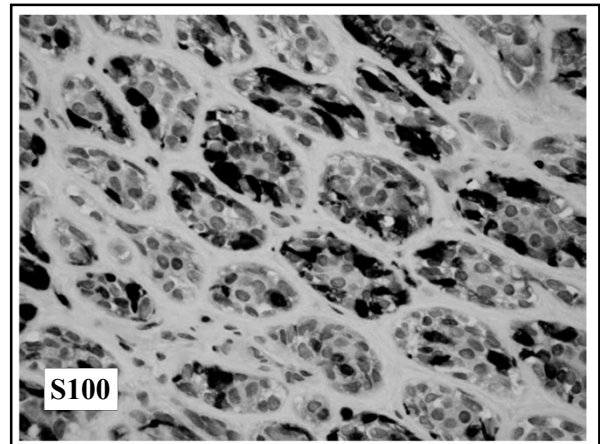
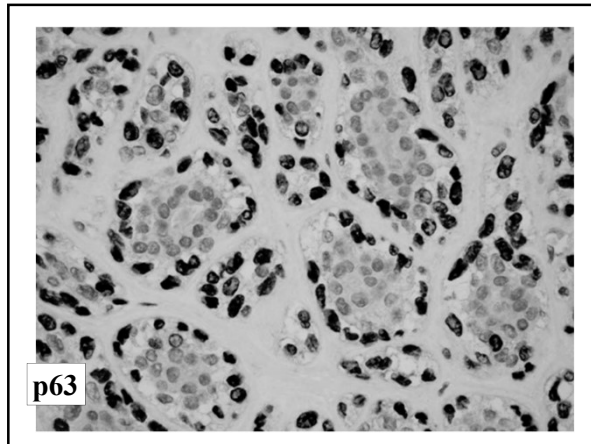
- Clear cell carcinomas
- Pleomorphic and monomorphic adenomas
- Oncocytoma
- Acinic cell carcinoma
- Mammary analogue secretory carcinoma
- Mucoepidermoid carcinoma
- Epithelial-myoepithelial carcinoma
- Myoepithelial carcinoma
- Metastatic renal cell carcinoma

Epithelial-Myoepithelial Carcinoma (EMC)



EMC





**Mucoepidermoid Carcinoma
Prognosis & Microscopic Grading**

- **Biologic behavior correlates to microscopic grade**
- **Exception is for submandibular gland MEC**

**Mucoepidermoid Carcinoma
Treatment and Prognosis**

- **Low or intermediate grade MEC:**
 - wide local excision
 - 90% 5-year survival

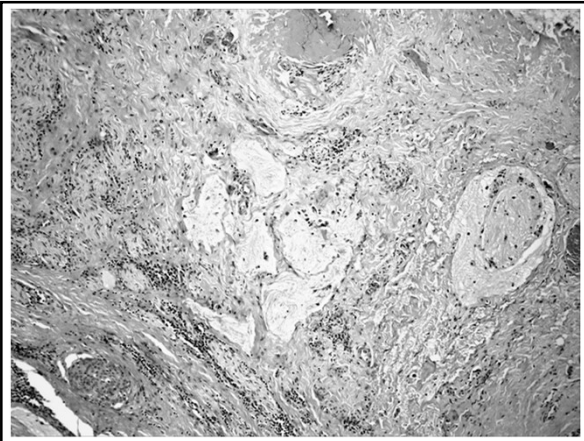
Mucoepidermoid Carcinoma Treatment and Prognosis

- **High-grade MEC:**
 - Wide block surgical excision to include nerves plus neck dissection
 - 40% 5-year survival

Mucoepidermoid Carcinoma CRTC1/MAML2 Translocation

- Identified in large proportion of MEC of the salivary gland
- Highly specific for MEC and imparts a better prognosis

Seethala RR, et al. Am J Surg Pathol 2010;34:1106-21

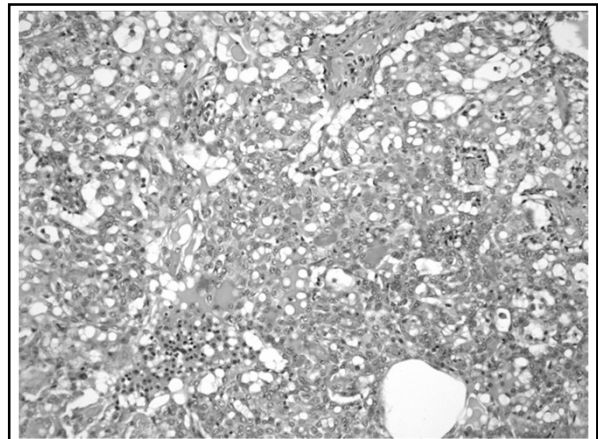


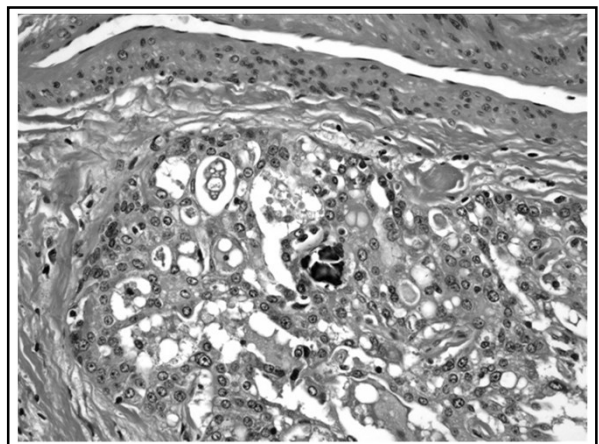
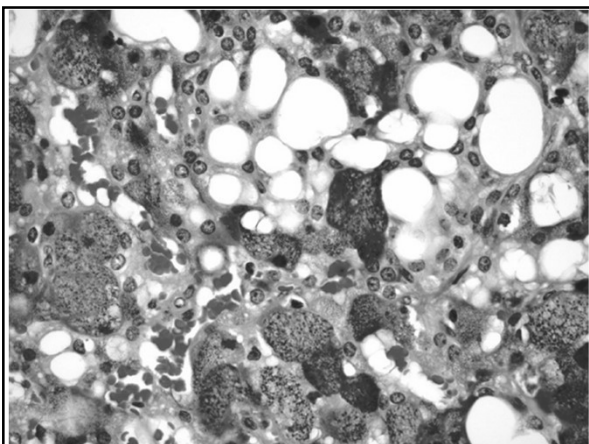
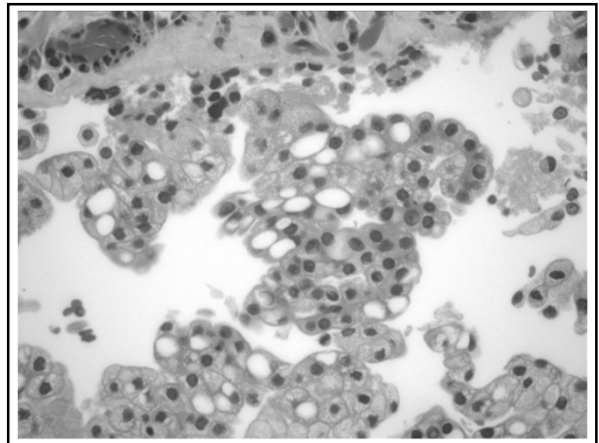
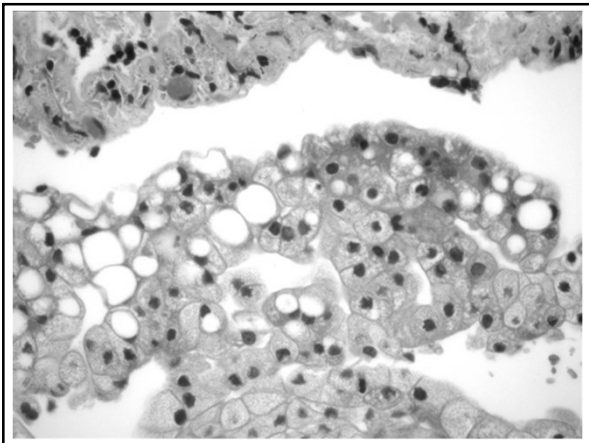
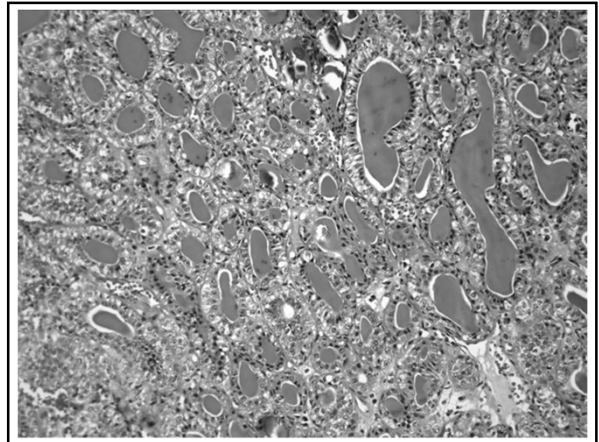
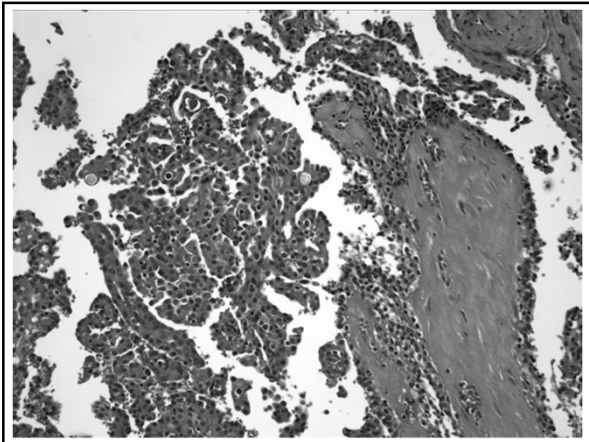
Acinic Cell Carcinoma Definition

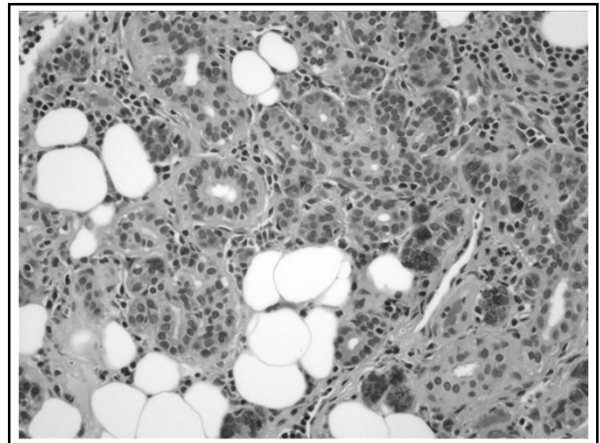
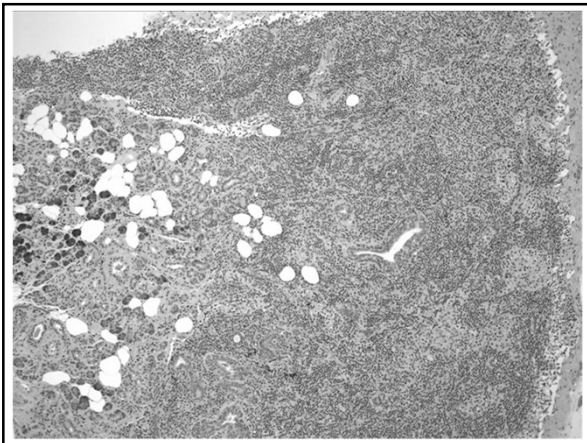
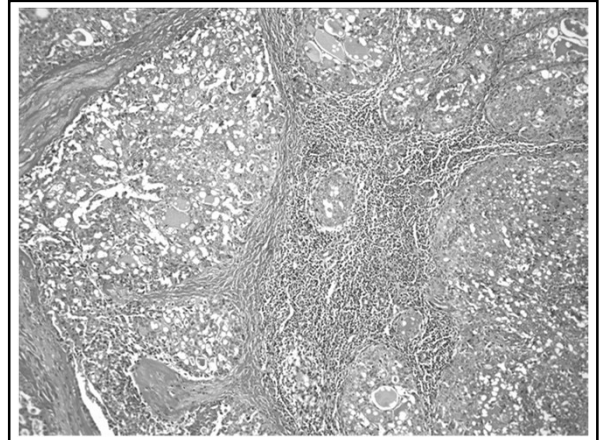
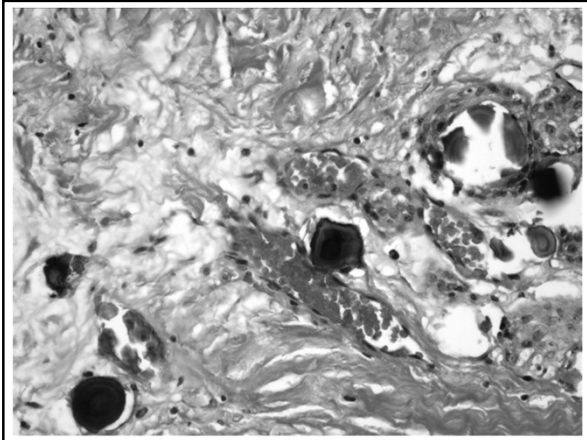
- Malignant epithelial salivary gland neoplasm characterized by a variety of histologic growth patterns and the tendency for at least some of the neoplastic cells to recapitulate the appearance of normal serous acinous cells characterized by the presence of cytoplasmic (zymogen type) secretory granules

Acinic Cell Adenocarcinoma Clinical Features

- Represents approximately 18% of all malignant salivary gland neoplasms and 6.5% of all salivary gland neoplasms
- F > M; wide age range from children to older adults with a peak incidence in the 7th decade of life
- Parotid gland (>80%); less common sites include submandibular, sublingual, intraoral
- Slow growing, solitary (nonfixed) mass:
 - months to years
 - pain and/or facial nerve involvement uncommon





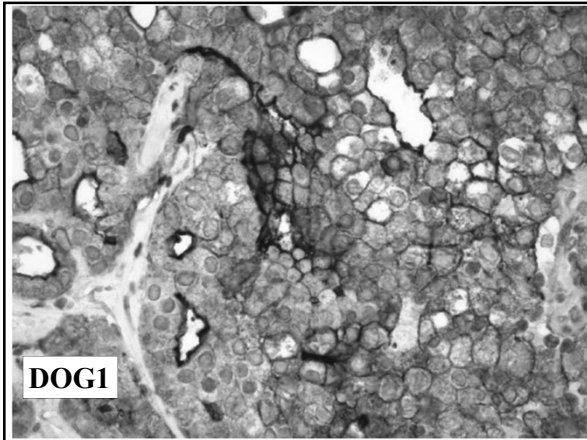


Acinic Cell Carcinoma Histochemistry

- Acinar cells and intercalated duct cells:
 - diastase-resistant, PAS-positive cytoplasmic granules
 - mucicarmine and alcian blue typically negative but may be weakly positive
 - presence of some intracytoplasmic mucicarminophilic material can be seen and does not exclude the diagnosis

Acinic Cell Carcinoma Immunohistochemistry

- **DOG1 (Discovered on GIST-1):**
 - marker of acinar cells
 - complex staining including apical membranous, cytoplasmic and complete membranous
- Cytokeratins, CEA, amylase
- Variable S100 protein, vimentin, mammaglobin, GATA3,
- p63, calponin, actins negative



Acinic Cell Carcinoma Molecular Genetics

- Absence of t(12;15) (p13;q25) ETV6-NTRK3 translocation

Acinic Cell Carcinoma Treatment and Prognosis

- Surgical excision treatment of choice
- Indolent neoplasms cured by surgery
 - approx. 35% recurrence rate
 - approx. 16% metastatic rate
 - approx. 16% disease-associated death rate
- 5-year disease specific survival of 91%
- High-grade transformation:
 - poor prognosis

Mammary Analogue Secretory Carcinoma (MASC)* Definition

- Distinctive salivary gland neoplasm with features resembling acinic cell adenocarcinoma and low-grade cystadenocarcinoma, and displaying strong similarities to secretory carcinoma of the breast

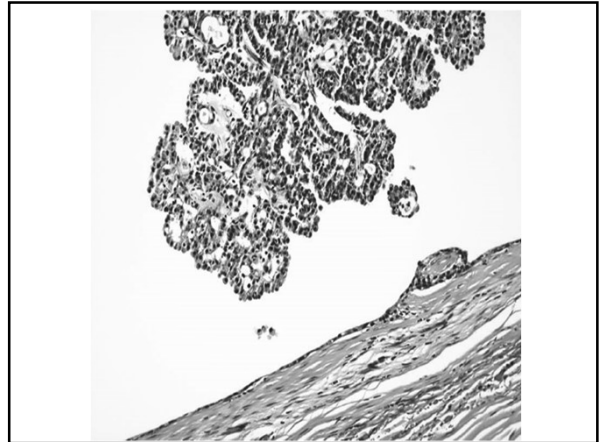
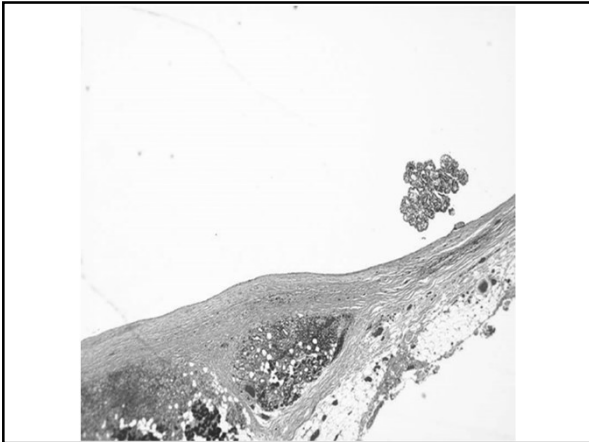
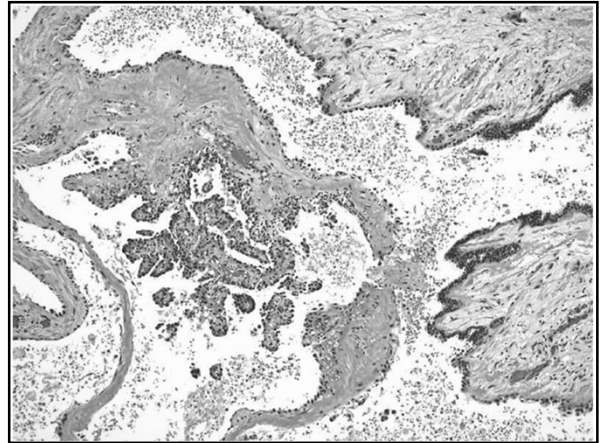
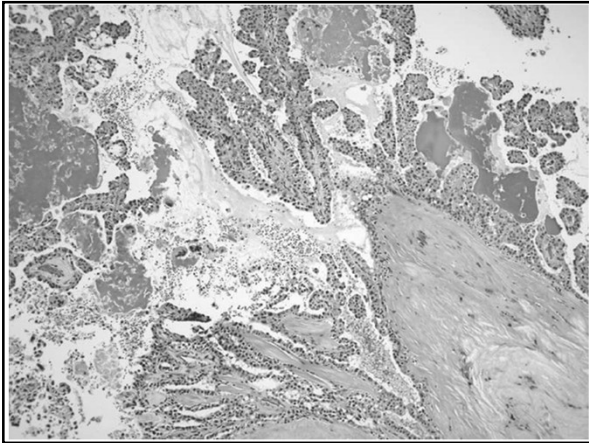
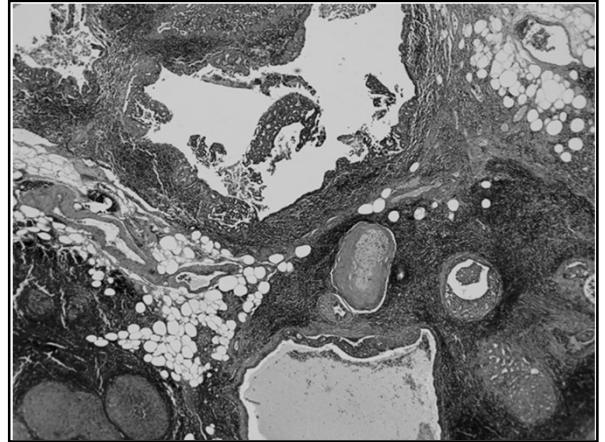
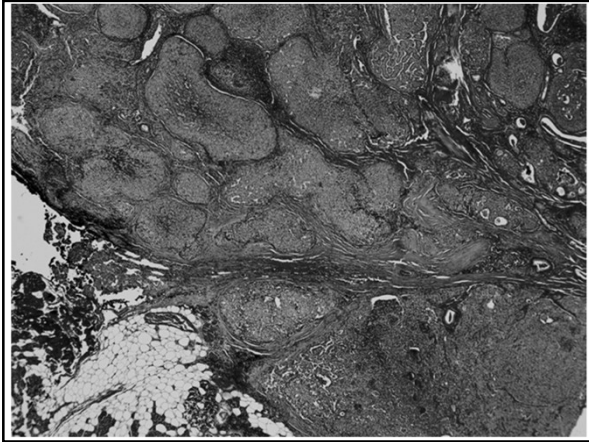
* Skalova et al. Am J Surg Pathol 2010;34:599-608

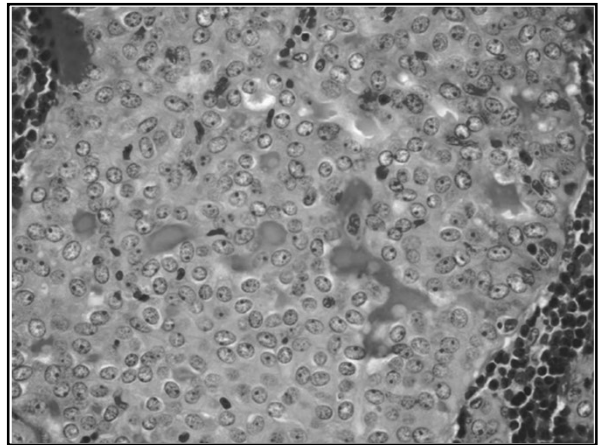
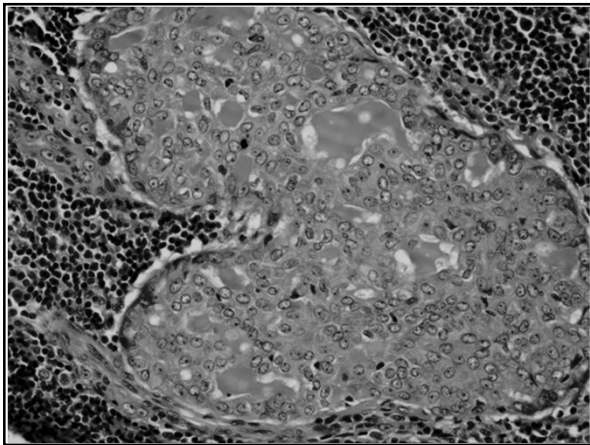
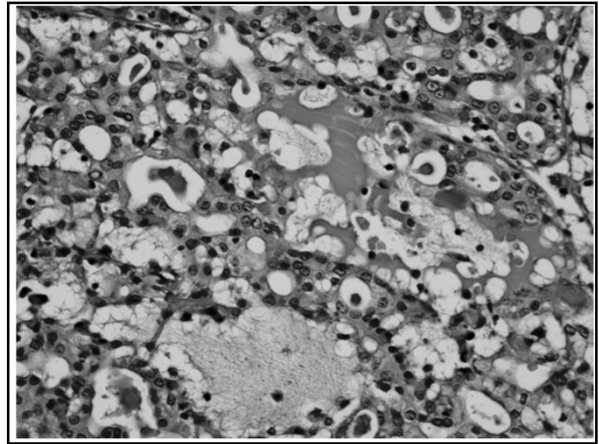
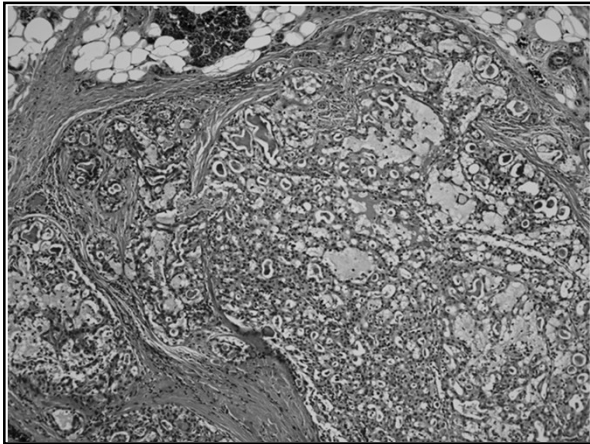
MASC Clinical Features

- M > F; age range 21-75 (mean, 46 years)
- Most common in parotid gland but may occur in other major glands as well as in minor salivary glands
- Most common presentation is as a painless mass
- No known cause(s)

MASC Histopathology

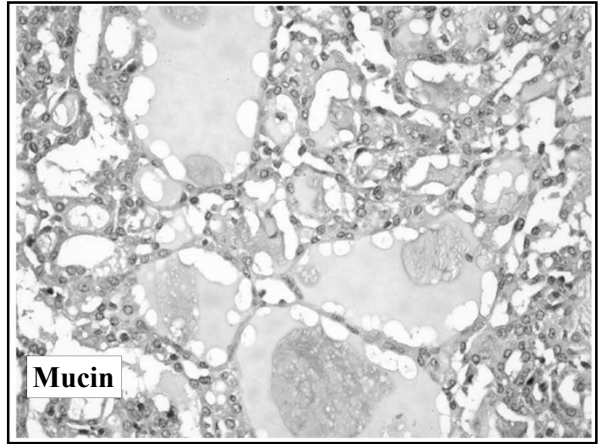
- Overlapping features with acinic cell carcinoma including:
 - growth patterns
 - cell types except for presence of cells with intracytoplasmic basophilic granules

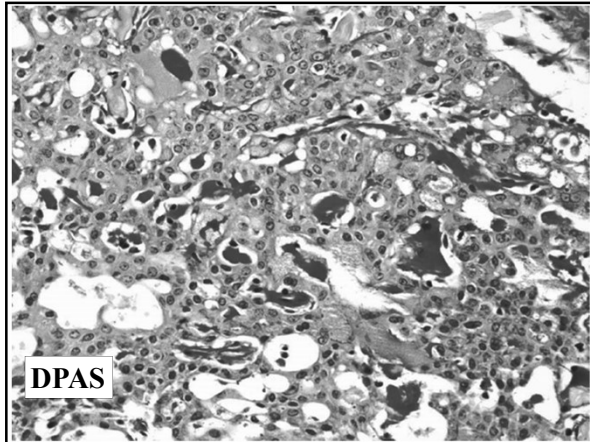




MASC
Histochemistry

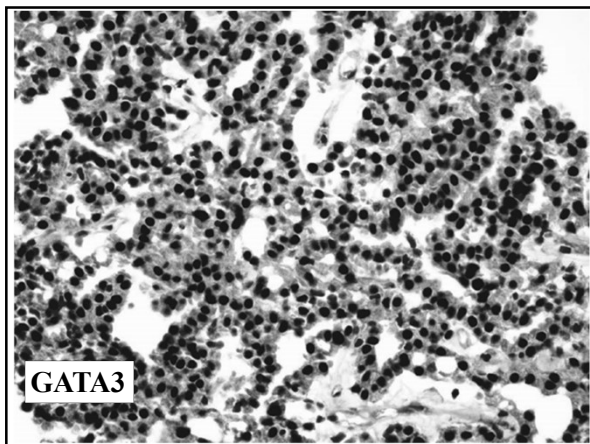
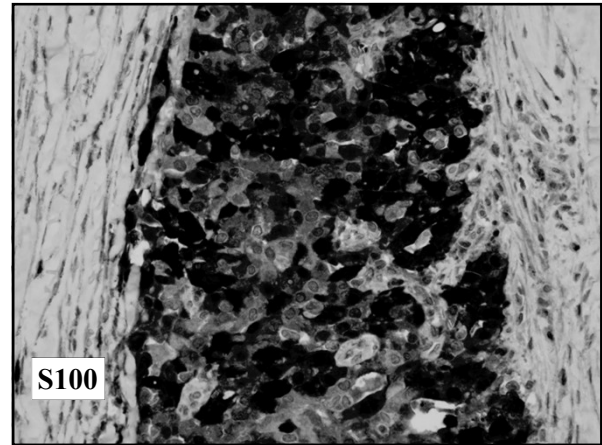
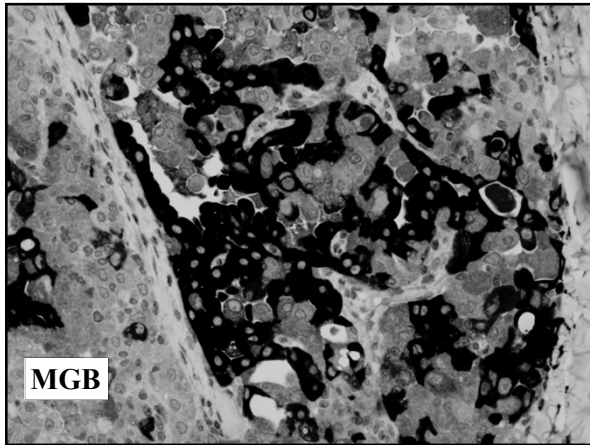
- **Intratubular secretory material:**
 - Diastase-resistant PAS-positive
 - Mucicarmine negative to weakly positive





MASC
Immunohistochemistry

- Mammaglobin and S100 protein:
 - diffuse and strong reactivity in conjunction with appropriate light microscopic features considered diagnostic even without molecular evaluation
- GATA binding protein 3 (GATA3):
 - consistent strong and diffuse staining (i.e., >50% of cells) limited to MASC and salivary duct carcinoma



MASC
Molecular Genetics

- **t(12;15) (p13;q25) ETV6-NTRK3 translocation**

MASC Differential Diagnosis

- **Acinic cell carcinoma**
- **Mucoepidermoid carcinoma**
- **Polymorphous low-grade adenocarcinoma**

MASC

- **Most/all “zymogen poor” acinic cell carcinomas are MASCs**
- **Prior to diagnosing acinic cell carcinoma of a non-parotid gland site, exclusion of other diagnostic considerations especially MASC is mandatory as many acinic cell carcinomas of non-parotid gland sites have been reclassified as MASCs**

MASC Treatment and Prognosis

- **Complete surgical resection**
- **Efficacy of radiotherapy uncertain**
- **Overall indolent clinical course reported:**
 - **mean disease-free survival of 92 months**
 - **majority of cases reported without evidence of disease from 27 months - 10 years**
 - **minority of cases with recurrent and/or metastatic disease**
- **High-grade transformation rare (3 cases):**
 - **poor prognosis**

Adenoid Cystic Carcinoma Definition

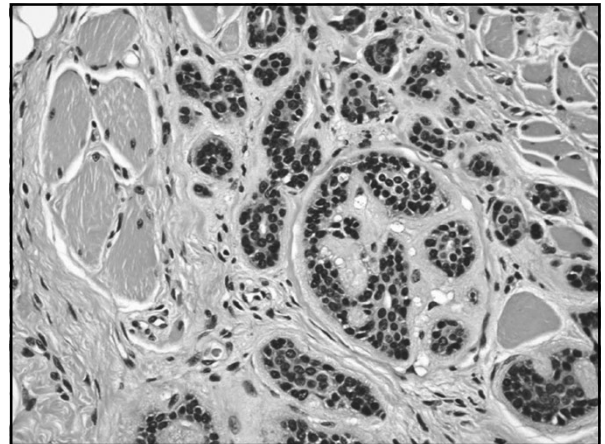
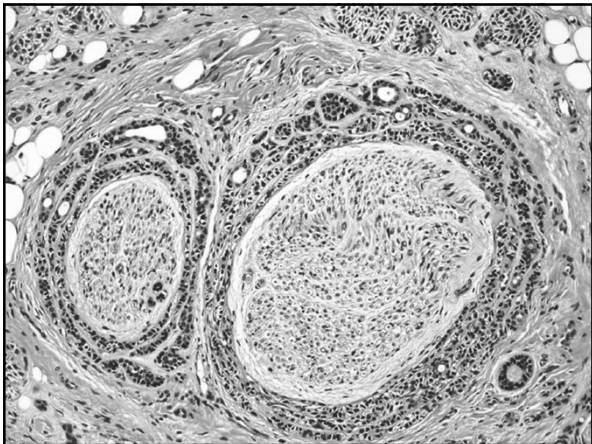
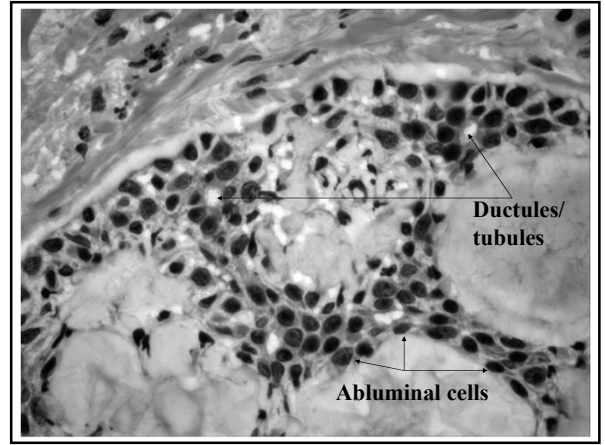
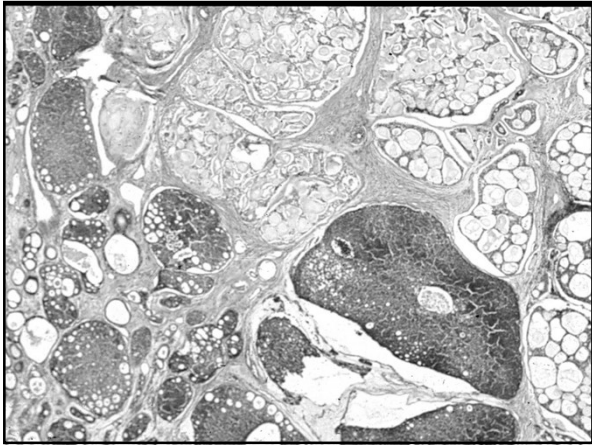
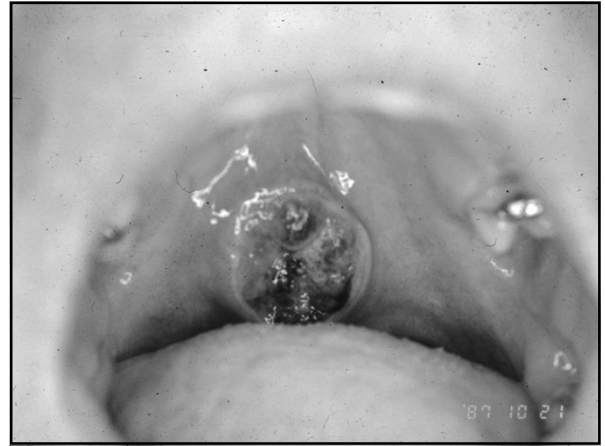
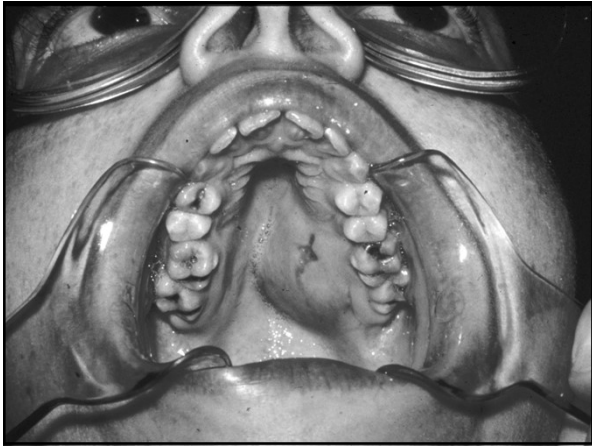
- **Malignant epithelial salivary gland neoplasm of myoepithelial (abluminal) and epithelial (luminal) cells characterized by its histologic appearance, tendency to invade nerves and protracted but nonetheless relentless clinical course**

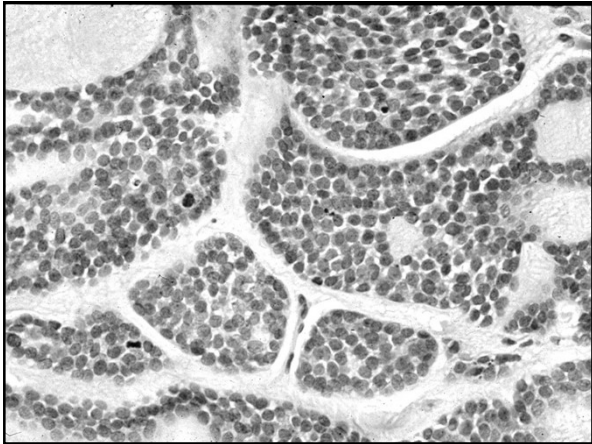
Adenoid Cystic Carcinoma Clinical Features

- **App. 10-12% of all malignant salivary gland tumors**
- **No gender predilection except for submandibular tumors which predilect to women**
- **Wide age range and most commonly occurs in the 5th-7th decades of life; uncommon < 3rd decade**
- **Major salivary glands - parotid and submandibular glands:**
 - **up to 5% of all parotid gland neoplasms;**
 - **approx. 15% of submandibular gland neoplasms and represents the most frequently encountered malignant neoplasm of the submandibular gland**

Adenoid Cystic Carcinoma Clinical Features Cont'd

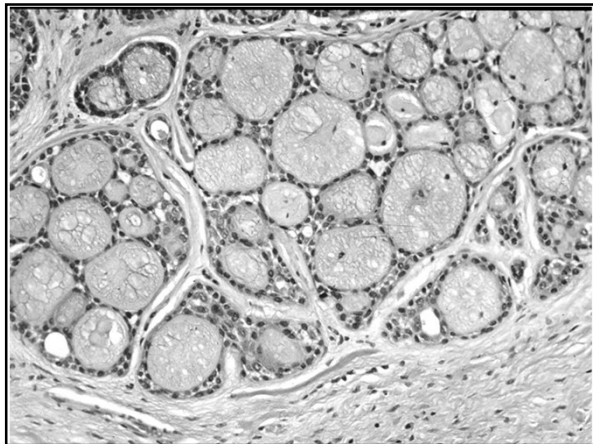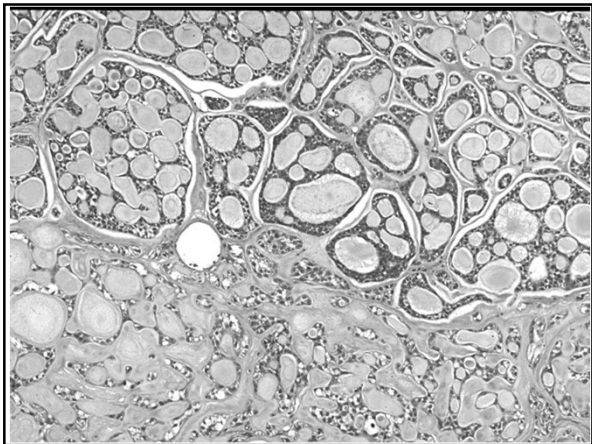
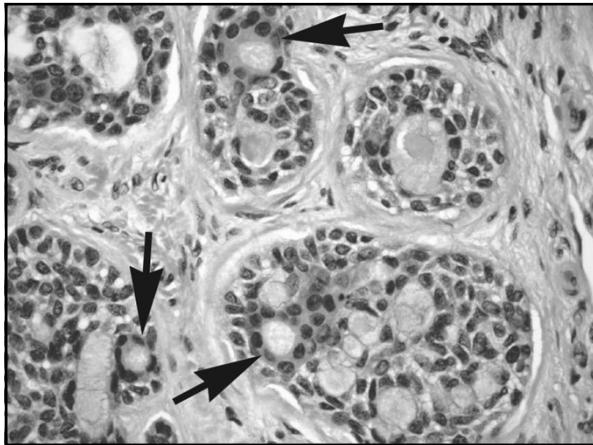
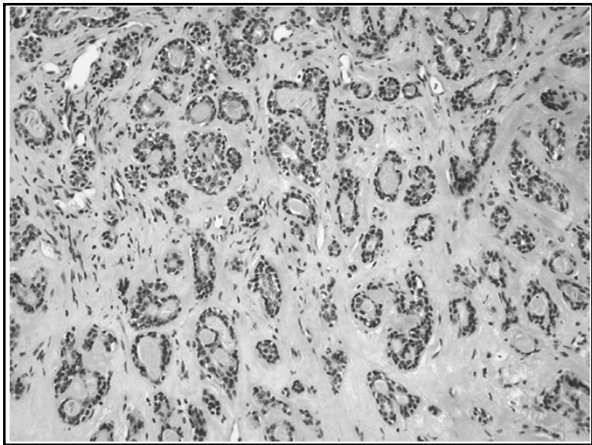
- **Accounts from 30% to nearly half of epithelial tumors of minor salivary gland tumors; may involve the minor salivary glands throughout the upper respiratory tract:**
 - **Most frequently involves the palate;**
 - **Other sites of involvement include tongue, sinonasal tract, ceruminal glands of the external auditory canal and the lacrimal gland;**
- **Accounts for 50% of all lacrimal gland neoplasms**

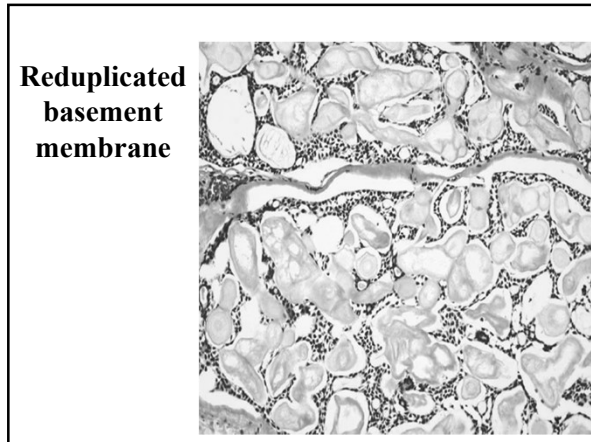




**Adenoid Cystic Carcinoma
Histologic Grading**

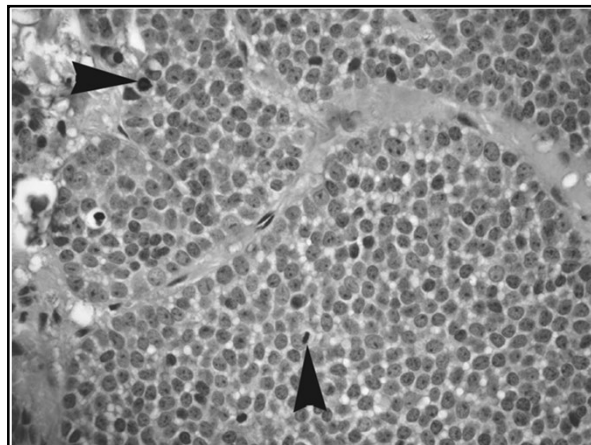
- **Grade 1:**
 - mostly tubular, some cribriform
 - absence of solid
 - absence of nuclear pleomorphism or mitotic activity
- **Grade II:**
 - pure cribriform pattern or mixed tubular/cribriform
 - solid patterns may be present but not >30%;
 - slightly greater nuclear pleomorphism and mitotic activity than Grade I





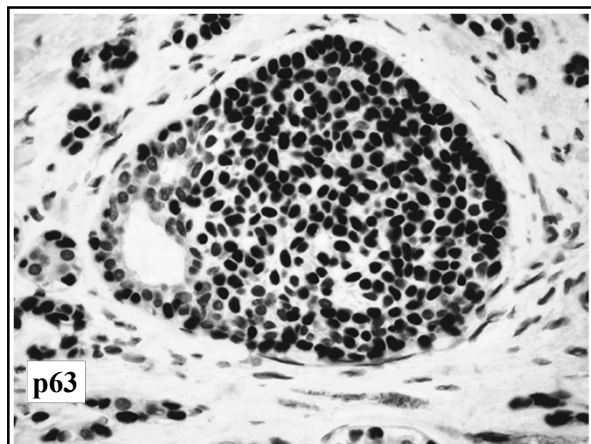
**Adenoid Cystic Carcinoma
Histologic Grading**

- **Grade III:**
 - > 50% solid;
 - more significant nuclear pleomorphism and increased mitotic activity than Grade II;
 - necrosis often present



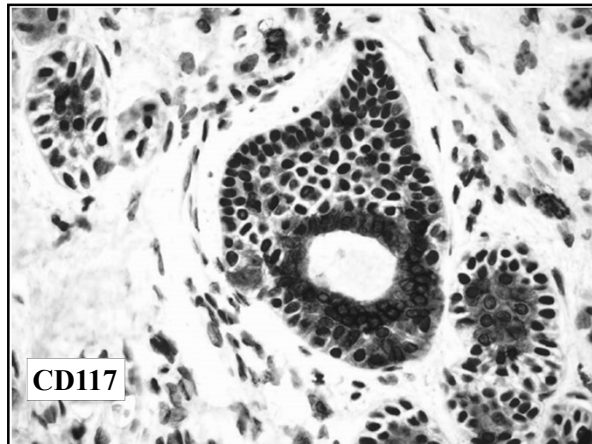
**Adenoid Cystic Carcinoma
Immunohistochemistry**

- **Myoepithelial or basal (abluminal) cells:**
 - cytokeratins, p63, p40, S100 protein, calponin, smooth muscle actin, smooth muscle myosin heavy chain and vimentin positive
 - cytokeratin tends to be less intensely reactive as compared to ductal cells
 - glial fibrillary acidic protein may be focally positive



**Adenoid Cystic Carcinoma
Immunohistochemistry**

- **Ductal (luminal) cells:**
 - Cytokeratins (pancytokeratin, CK7, CK14, CK17, CK19), S100 protein, epithelial membrane antigen (EMA), CEA and c-kit (CD117) positive:
 - cytokeratin tends to be more intensely reactive as compared to myoepithelial or basal cells



Adenoid Cystic Carcinoma Molecular Genetics

- Specific chromosomal translocation $t(6;9)(q22-23;p23-24)$ involving the v-myb avian myeloblastosis viral oncogene homolog (MYB) and nuclear factor I/B (NFIB) genes results in *MYB-NFIB* gene fusion identified in adenoid cystic carcinomas:
 - identified in adenoid cystic carcinomas irrespective of site of occurrence
 - gene fusion found in 30-50% of cases with increase to 86% when performed on frozen specimen

Adenoid Cystic Carcinoma Differential Diagnosis

- Pleomorphic adenoma
- Monomorphic adenomas
- Polymorphous low-grade adenocarcinoma
- Adenocarcinoma, not otherwise specified

Adenoid Cystic Carcinoma Treatment and Prognosis

- Wide excision
- Radiotherapy useful in controlling microscopic disease after initial surgery, in treating locally recurrent disease or as palliation management in unresectable tumors
- Chemotherapy is utilized as palliation in patients with advance disease

Adenoid Cystic Carcinoma Treatment and Prognosis Cont'd

- Recurrence rates range from 16-85%
- Regional lymph node metastases uncommon ranging from 5-25%
- Distant metastasis ranges from 25-55%
- Survival rates:
 - 5-year overall survival: 60-90%
 - 10-year overall survival: 29-80%
 - 15-year overall survival: 29-55%

Adenoid Cystic Carcinoma Treatment and Prognosis Cont'd

- VIIⁿ paralysis: may be associated with worse prognosis and quicker demise
- Histologic grade:
 - Grades 1-2: 15 year survival rates:
 - Grade I: 39%
 - Grade II: 26%

Adenoid Cystic Carcinoma Treatment and Prognosis Cont'd

- Grade 3:
 - higher incidence of metastasis:
 - may metastasize even in clinically lower stage tumors (e.g., T1, T2)
 - earlier fatal outcomes:
 - 14% 5-year survival
 - 5% 15 year survival

Adenoid Cystic Carcinoma Treatment and Prognosis Cont'd

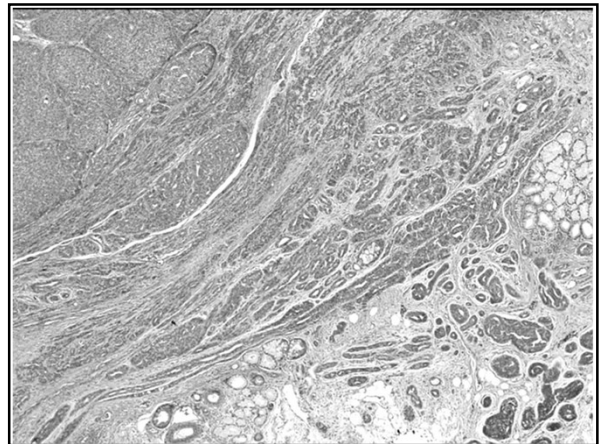
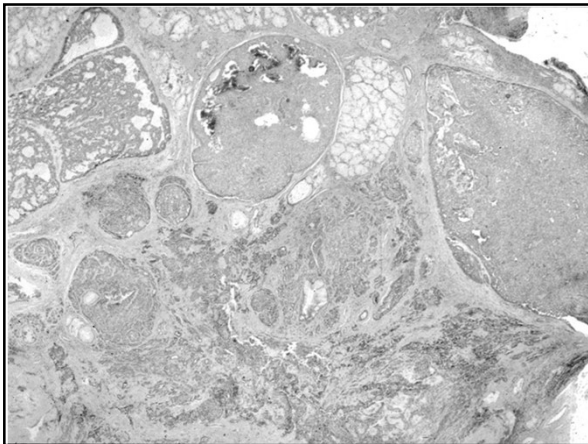
- Clinical stage:
 - advanced stage associated with poorer outcome
 - Stage I: 75% 10-year survival;
 - Stage II: 43% 10-year survival;
 - Stages III-IV: 15% 10-year survival.
- Positive surgical margins and/or failure of local disease control following initial surgery:
 - recurrent tumor is generally a sign of incurability

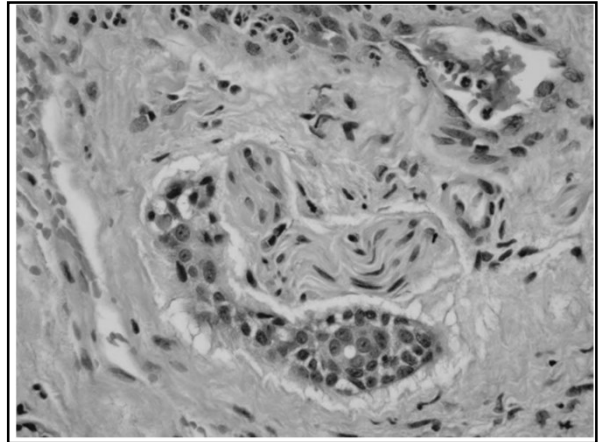
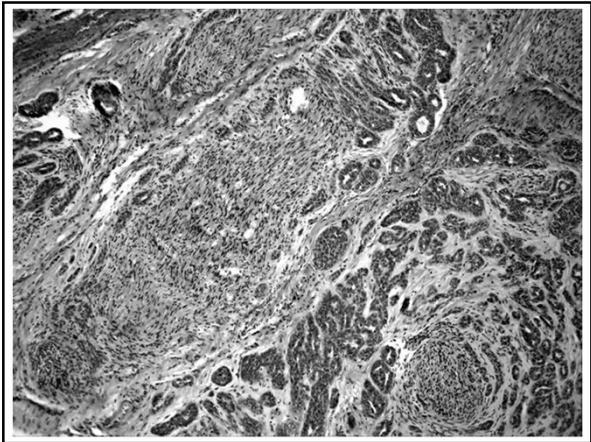
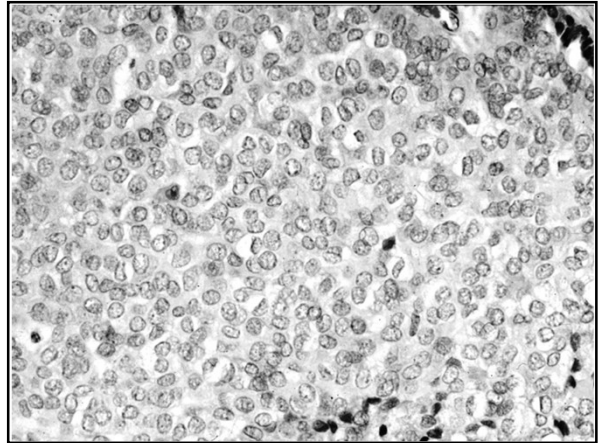
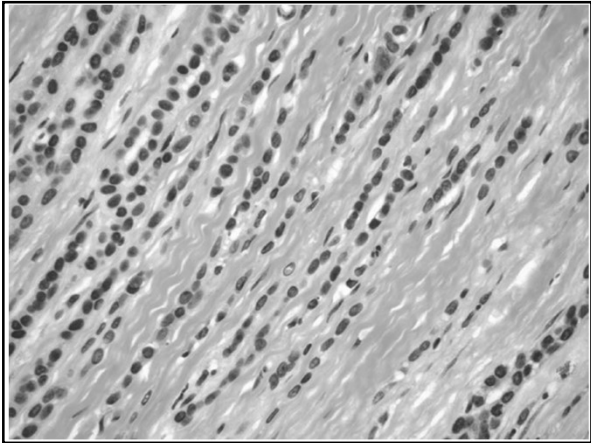
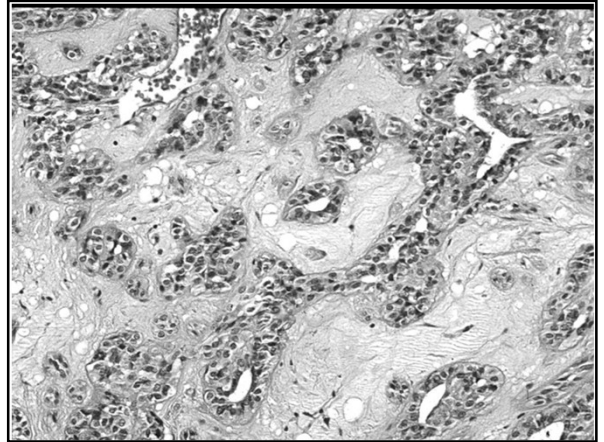
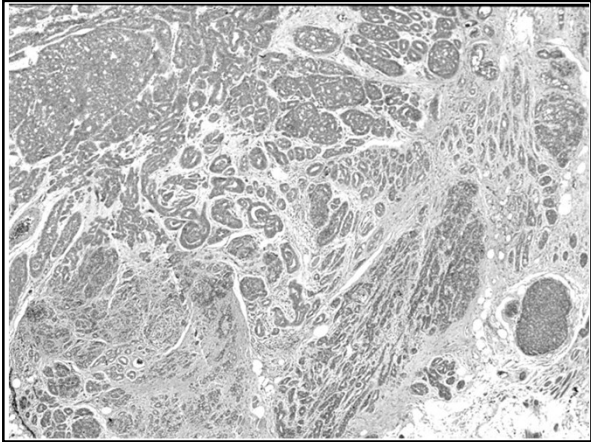
Polymorphous Low-Grade Adenocarcinoma (PLGA) Definition

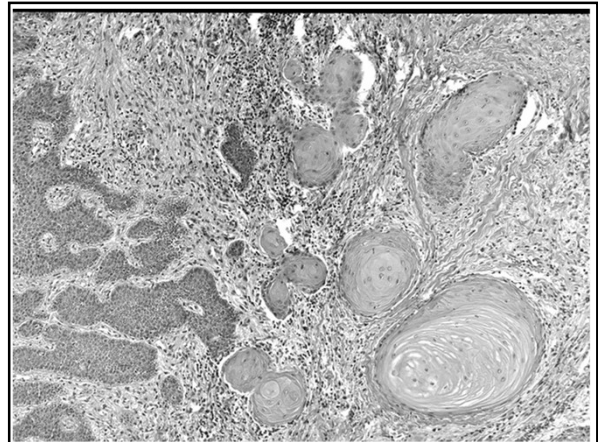
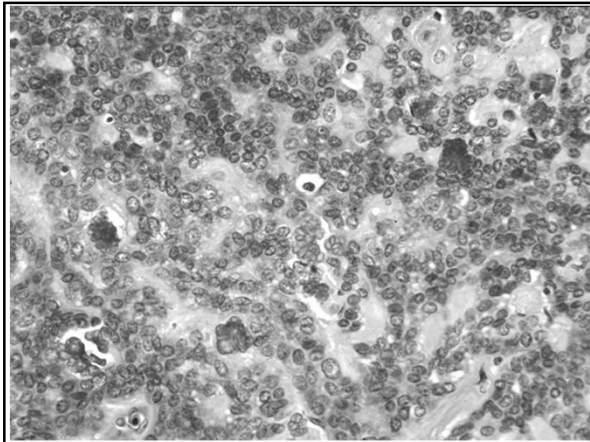
- Malignant epithelial neoplasm of (minor) salivary gland origin characterized by its diverse (polymorphous) architecture, bland cytopathology, infiltrative growth and indolent behavior
- Formerly referred to as:
 - Terminal duct adenocarcinoma
 - Lobular carcinoma

PLGA Clinical Features

- Increasingly recognized
- F > M; occurs over a wide age range
- Sites:
 - intraoral minor salivary glands (palate > other sites)
 - Major glands: malignant component in carcinoma ex mixed tumor
 - de novo neoplasm
- Symptoms: painless mass, bleeding, otalgia, paresthesia, pain
- No known etiologic factors







PLGA
Immunohistochemistry

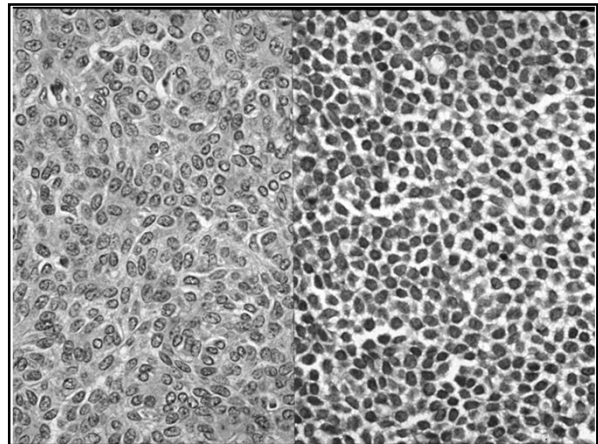
- Cytokeratins, EMA, S-100 protein, vimentin positive
- variable CEA and MSA
- p63 and p40:
 - variable p63 reactivity but usually at least focally present
 - p40 negative
- Usually negative for other markers of myoepithelial cells (calponin, SMA, SMMS1)
- GFAP typically negative

PLGA
Differential Diagnosis

- Adenoid cystic carcinoma
- Pleomorphic adenoma
- Monomorphic adenomas
- Cribriform adenocarcinoma of minor salivary glands (CAMSG)

Pairing p63 and p40

- IHC pairing p63 and p40 reported to assist in differentiating pleomorphic adenoma (PA) from polymorphous low-grade adenocarcinoma (PLGA) and adenoid cystic carcinoma (AdCC)
 - PA: p63 +; p40+
 - Cellular PA: p63+; p40+ or p63- ; p40-
 - PLGA: p63+; p40-
 - AdCC: p63 +; p40+



**PLGA
Treatment and Prognosis**

- **Complete surgical resection treatment of choice:**
 - radiation reserved for those tumors with inadequate surgical margins or for recurrent tumors;
 - neck dissection is not indicated unless there is evidence of cervical adenopathy

**PLGA
Treatment and Prognosis**

- **Indolent neoplasm:**
 - local recurrence (9-17%)
 - regional metastasis (9-15%):
 - may occur in absence of local recurrence
 - may occur years following diagnosis
 - Death due to PLGA rarely occurs
 - Rarely:
 - Malignant component of CEPA;
 - Transformation to histologically higher grade

**PLGA
Treatment and Prognosis**

- Overall prognosis is excellent:
 - indolent behavior: 95% 10-year survival
 - local recurrence rate between 9% and 17%:
 - due to its slow growth rate, local recurrence typically occurs several years following initial treatment
- Regional metastatic rate from 9% to 15%
 - may occur years following initial treatment
- Distant metastases seldom reported
- Death attributed to tumor unusual and occurs after prolonged periods

**Salivary Gland Neoplasms
Conclusions**

- Salivary gland lesions are diverse with overlapping clinical and pathologic features
- Diagnosis and DDX usually by made by light microscopic findings:
 - Histomorphologic criteria supplemented by IHC
 - Criteria for malignancy
 - Emerging role of molecular biology in diagnosis and differential diagnosis

**Chromosomal Translocation in
Salivary Gland Neoplasms**

Tumor Type	Gene Fusion
• Pleomorphic adenoma	• <i>PLAG1; HMGA2</i>
• Mucoepidermoid carcinoma	• <i>CRTC1-MAML2</i>
• Adenoid cystic carcinoma	• <i>MYB-NFIB</i>
• MASC	• <i>ETV6-NTKR3</i>
• Hyalinizing clear cell carcinoma; clear cell myoepithelial carcinoma	• <i>EWSR1-ATF1</i>